EUROPEAN SOCIETY OF RADIOLOGY

European Training Curriculum for Radiology

Curriculum for the Level I Training Programme (Years 1–3)

Curriculum for the Level II Training Programme (Years 4–5)

EDITION FEBRUARY 2020

PREFACE TO THE LEVEL I AND II

We are pleased to present this new edition of the ESR European Training Curriculum (ETC) Level I and II with revised content to the radiological community.

The ETC defines the contents of training and expected learning outcomes of trainees in radiology and its ultimate goal is to achieve, throughout all European countries, a standardised system of education in the field of radiology, which will enhance the quality of radiological care for patients.

The ETC is a living document, which is continuously revised by the ESR Subspecialties and Allied Sciences Member Societies in order to keep up with the current developments and knowledge in the field of radiology.

Accordingly, the 2020 edition of the ETC contains several important updates.

As recommended by the UEMS (European Union of Medical Specialists) Council, we added a definition of general radiology and the ESR Subspecialties and Allied Sciences Member Societies contributing to the development of the ETC provided introductions for their respective chapters. In addition, the content of the individual chapters was updated by the respective ESR Subspecialties and Allied Sciences Societies, where necessary, in order to reflect the latest developments in the respective sub-fields.

Lastly, the chapter on Medical Imaging Informatics, first introduced by the European Society of Medical Imaging Informatics (EuSoMII) in the 2018 edition of the ETC, underwent a substantial revision and its content was redefined by the ESR eHealth and Informatics Subcommittee in collaboration with EuSoMII.

I would like to take this opportunity to thank the ESR Board of Directors and the ESR Executive Council as well as the ESR Subspecialties and Allied Sciences Member Societies, the members of the eHealth and Informatics Subcommittee and all individuals involved for their contribution to this updated version of this continuously evolving document in the past and this year.

Our specialty is in constant development and the technological advances require an ongoing adaptation of the training model which we achieve through the valuable support of the European Society of Radiology.

Rome, March 2020

Carlo Catalano
Chairperson of the ESR Education Committee
(March 2018 – March 2021)

I. TRAINING REQUIREMENTS FOR TRAINEES

1. CONTENT OF TRAINING AND LEARNING OUTCOME

This chapter defines the contents of training and expected learning outcomes of trainees in radiology. Training shall be performed at several levels. The revised European Training Curriculum for Radiology continues to outline a five year (3 + 2) training period, consisting of Level I Training over the first three years followed by a more flexible Level II Training with potential special interest (elective) rotations during the last two years. Full subspecialty training with consecutive subspecialisation can be performed after this five-year training period, which corresponds to Level III training (not part of this curriculum). By general radiology, it is meant radiology training in all different subspecialties, without a specialised focus.

In international higher and post-graduate education there has been an increasing focus on competencies, rather than just education inputs. Instead of just focussing on the "learning inputs", the "learning outputs" have increasingly been in the centre of educational attention and endeavours. This led to concepts of Knowledge, Skills and Competences (KSCs) or of Knowledge, Skills and Attitudes (KSAs). These learning outcomes are less dependent on the times and routes of acquisition.

While the concept of "knowledge" has been the traditional basis for educational curricula providing lists of topics the trainee is expected to learn, the concepts of skills, competences and attitudes are more difficult to appreciate. The word "skill" is usually applied to describe a level of performing a particular task – this can be a motor task (e.g. performing an arterial puncture) or a cognitive task. The term "competences" has been subject to frequent debates in the past years with several different models being in use.

Competences tend to develop from an initially rule-based, inflexible behaviour to an intuitive under-standing of the situation and comprehension of the crucial aspects of a situation. This development should be encouraged throughout the training.

The following training curriculum / syllabus is divided into two levels of training (Level I and Level II) and further subdivided into the different areas of training. These chapters are further divided into the following sections:

- Knowledge: this section includes the main domains of theoretical knowledge the trainee should master in this specialty area
- Skills: this section includes the key practical and clinical skills the trainee should acquire in this specialty area
- Competences and attitudes: this section includes the competences to be mastered as well as the domains of professionalism the trainee should acquire in this specialty area

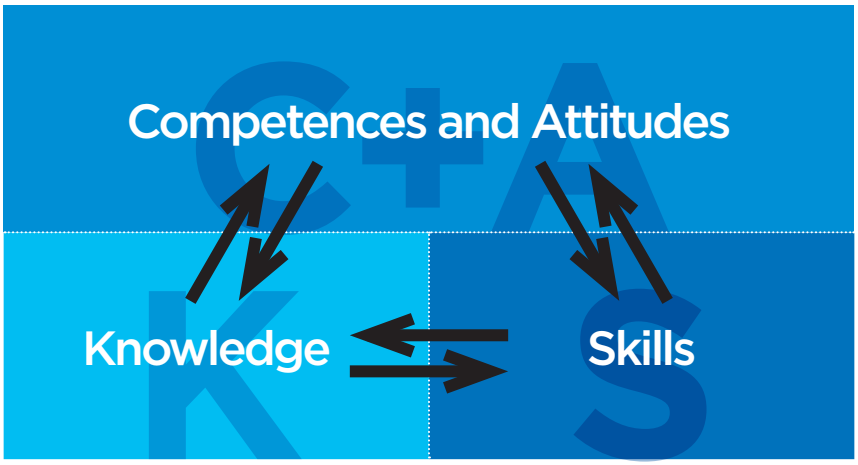

B-I:
LEVEL I TRAINING (YEARS 1–3)

B-I-3
CHEST RADIOLOGY

INTRODUCTION

The aim of this curriculum in chest imaging is to ensure that the trainee develops core knowledge of the relative value of available imaging modalities with regard to normal chest and chest diseases. This knowledge will form the basis for further training (if desired) and also provide transferable skills that will equip the trainee to work as a specialist in any branch of radiology.

Physics, contrast media and radiation protection are covered in separate sections, and therefore are not included in detail in this section, unless of particular relevance to chest imaging.

KNOWLEDGE

- To describe the anatomy of the respiratory system, heart and vessels, the mediastinum and the chest wall on radiographs, CT and MRI
- To describe normal variants of the respiratory system, heart and vessels, the mediastinum and the chest wall
- To understand the mean exposure doses of chest radiographs and of chest CT examinations
- To understand techniques to reduce exposure doses of chest radiographs and of chest CT examinations
- To describe the principles of digital imaging and image processing pertinent to chest radiology
- To understand the significance of generic signs on chest radiographs and CT

GENERIC SIGNS ON CHEST IMAGING

- To confidently identify the following structures on postero-anterior (PA) and lateral chest radiographs:
  - » Right upper, middle and lower lobes; left upper and lower lobes; and lingula
  - » Fissures – major, minor and azygos
  - » Airway – trachea, main bronchi, posterior wall of the intermediate bronchus and lobar bronchi
  - » Heart – position of the atria, ventricles, left atrial appendage and the location of the four cardiac valves
  - » Pulmonary arteries – main, right, left and interlobar
  - » Aorta – ascending, arch and descending aorta
  - » Arteries – brachiocephalic (innominate), carotid and subclavian arteries
  - » Veins – superior and inferior vena cava, azygos, left superior intercostal ("aortic nipple") and left brachiocephalic (innominate) veins
  - » Components of the thoracic skeleton
  - » Mediastinal stripes and interfaces
  - » Aortopulmonary window
  - » Both hemidiaphragms

- To have an in-depth understanding of the significance of the following chest radiography signs:
  - » Silhouette sign – loss of the contour of the heart or diaphragm indicating an adjacent abnormality (e.g. atelectasis of the right middle lobe obscures the right-hand side of the heart's border)
  - » Air bronchogram – indicates airless alveoli and, therefore, a parenchymal process as distinguished from a pleural or mediastinal process
  - » Air crescent sign – indicates solid material in a lung cavity, often due to a fungus ball, or crescentic cavitation in invasive fungal infection
  - » Cervicothoracic sign – a mediastinal opacity that projects above the clavicles, situated posterior to the plane of the trachea, while an opacity projecting at or below the clavicles is situated anteriorly
  - » Tapered margins – a lesion in the chest wall, mediastinum or pleura may have smooth tapered borders and obtuse angles with the chest wall or mediastinum, while parenchymal lesions usually form acute angles
  - » Gloved finger sign – indicates bronchial impaction, e.g. in allergic bronchopulmonary aspergillosis, or other chronic obstructive processes
  - » Golden sign – indicates lobar collapse with a central mass, often due to an obstructing bronchogenic carcinoma in an adult
  - » Deep sulcus sign on a supine radiograph – indicates pneumothorax
- To describe monitoring and support devices ("tubes and lines") and to confidently identify them on imaging studies
- To describe the imaging features and the preferred placement of the following devices and lines and to list the complications associated with the malpositioning of each of the following:
  - » Endotracheal tube
  - » Central venous catheter
  - » Swan–Ganz catheter
  - » Nasogastric tube
  - » Chest tube/drain
  - » Intra-aortic balloon pump
  - » Pacemaker and pacemaker leads
  - » Implantable cardiac defibrillator
  - » Left ventricular assistant device
  - » Atrial septal defect closure device ("clamshell device")
  - » Pericardial drain
  - » Extracorporeal life support cannulae
  - » Intra-oesophageal manometer, temperature probe or pH probe
  - » Tracheal or bronchial stent
- To describe the typical chest radiography appearances of pleural effusion on erect, supine and lateral decubitus chest radiographs, and to list four causes of a large unilateral pleural effusion
- To describe the imaging features of pleural-based masses with bone destruction or infiltration of the chest wall on a radiograph or chest CT and to list four likely causes
- To describe the imaging features of a unilateral elevation of one hemidiaphragm on chest radiographs and to list five causes (e.g. subdiaphragmatic abscess, diaphragm rupture, phrenic nerve involvement with lung cancer, post-cardiac surgery and eventration)
- To describe the imaging features and clinical features of tension pneumothorax
- To describe the normal dimensions of the thoracic aorta
- To have an in-depth understanding of the Stanford A and B classification of aortic dissection and the implications of the classification for medical versus surgical management
- To comprehend the features on radiographs and CT and the differential diagnosis of diffuse interstitial and alveolar lung disease, airways and obstructive lung disease
- To differentiate solitary and multiple pulmonary nodules, benign and malignant neoplasms, hyperlucencies and their potential aetiology and evaluation

- To differentiate thoracic diseases in immunocompromised patients and congenital lung disease
- To analyse and explain disorders of the pulmonary vascular system and great vessels
- To understand the diagnostic role of radiographs, radionuclides, CT and MRI in the diagnostic evaluation of disorders of the pulmonary vascular system and great vessels
- To differentiate abnormalities of the chest wall, mediastinum and pleura

SKILLS

- To plan and to supervise the proper acquisition of radiographs, chest radiographs, ventilation / perfusion imaging, thoracic CT, high-resolution chest CT and the CT pulmonary angiography (CTPA)
- To perform proper positioning of chest radiographs and of chest CT examinations for adults, newborns, infants and children
- To plan and to protocol a CT examination of the chest and to adapt it to the individual situation
- To plan and to protocol an MRI examination of the chest and to adapt it to the individual situation
- To perform proper common post-processing tasks for thoracic imaging studies, including multiplanar reformations (MPR), maximum intensity projections (MIP), minimum intensity projections (MinIP) and vessel analysis tools
- To perform ultrasonographic examinations in the diagnosis
- To perform aspirations of pleural fluid under image-guidance

COMPETENCES AND ATTITUDES

- To justify diagnostic imaging examinations and/or interventional procedures of the chest
- To choose the best-suited method for evaluating disorders of the chest
- To communicate with the patient in order to obtain informed consent prior to diagnostic imaging and interventional procedures of the chest
- To choose optimal imaging parameters for radiographic, ultrasonographic, CT and MRI examinations of the chest
- To design imaging protocols for CT examinations of the thorax, including the appropriate application of intravenous contrast, spatial and temporal resolution, inspiration/expiration and reconstruction/reformatting techniques
- To apply techniques to reduce exposure doses for radiographic and CT examinations of the chest
- To supervise and teach technical staff to ensure that appropriate images are obtained
- To interpret and report radiographs, chest radiographs, ventilation/perfusion imaging, thoracic CT, high-resolution chest CT and CT pulmonary angiography (CTPA) with respect to common diseases
- To appreciate own limitations and to identify when it is appropriate to obtain assistance in interpreting and reporting images of the chest
- To identify urgent and/or unexpected findings in imaging examinations of the chest and to communicate these timely and properly
- To communicate with patients and their relatives in order to explain their imaging findings of the chest
- To choose optimal biopsy routes and techniques
- To participate in and to perform under supervision at multi-disciplinary conferences and tumour boards for diseases of the chest

B-II:
LEVEL II TRAINING (YEARS 4–5)

B-II-3
CHEST RADIOLOGY

INTRODUCTION

In Level II the trainee should, in addition to the knowledge, competencies and skills acquired in the first 3 years of training, have in-depth knowledge of the following:

- Normal anatomy and common variants of the chest, including lungs, heart, mediastinum, pleura, mains vessels, thoracic wall and skeletal structures
- The pathology and radiological presentation of lung, mediastinal and pleural diseases and the standard treatments available
- The radiological presentation of pathology of main vessels, thoracic wall and skeletal structures and the treatments available
- The understanding of imaging features of the traumatic chest injury
- Staging of lung cancer and the role of imaging
- An understanding of the expected changes after surgery, radiation and interventional procedures

Trainees should be able to perform, interpret and report on chest radiographs, ultrasound, CT and chest MRI for common clinical indications as well as rare clinical indications (under supervision).

Trainees should be able to confidently justify diagnostic imaging examinations and/or interventional procedures of the chest and choose the best-suited imaging method to achieve the best diagnosis while applying techniques to reduce exposure doses when applicable and possible.

KNOWLEDGE

NORMAL ANATOMY

- To describe the anatomy of the lobar and segmental bronchi
- To describe the topographic relationships of the hilar vessels and bronchi
- To describe the pulmonary lobule and its component parts
- To describe the terminology for describing the site and size (adenopathy, enlarged lymph node, normal lymph node) of mediastinal and hilar lymph nodes
- To describe the normal variants of aortic arch branching, including the common origin of the brachiocephalic and left common carotid arteries (“bovine arch”) and separating the origin of the vertebral artery from the arches
- To confidently identify the following structures on chest CT:
  - » All pulmonary lobes and segments
  - » A pulmonary lobule and associated structures
  - » Fissures – major, minor, azygos and common accessory fissures
  - » Extrapleural fat
  - » Inferior pulmonary ligaments

- » Airway – trachea, carina, main bronchi, lobar bronchi and segmental bronchi
- » Heart – left and right ventricles, left and right atria, atrial appendages
- » Pericardium – including superior pericardial recesses
- » Pulmonary arteries – main, right, left, interlobar, segmental
- » Aorta – sinuses of Valsalva, ascending, arch and descending aorta
- » Arteries – brachiocephalic (innominate), common carotid, subclavian, axillary, vertebral, internal mammary arteries
- » Veins – pulmonary, superior vena cava, inferior vena cava, brachiocephalic, subclavian, internal jugular, external jugular, azygos, hemi-azygos, left superior intercostal, internal mammary
- » Oesophagus
- » Thymus
- » Normal mediastinal and hilar lymph nodes
- » Azygo-oesophageal recess

ALVEOLAR LUNG DISEASES AND ATELECTASIS

- To list four common causes of segmental consolidation
- To list five of the most common causes of adult (acute) respiratory distress syndrome
- To list four predisposing causes of or associations with organising pneumonia
- To describe the most common causes of bronchiectasis
- To describe the imaging features and basic clinical features of centrilobular, paraseptal and panacinar emphysema
- To describe the imaging findings used to identify surgical candidates for giant bullectomy or lung volume reduction
- To describe the imaging patterns of segmental and lobar consolidation
- To describe the imaging features of partial or complete atelectasis of single or combined lobes on chest radiographs and to list the likely causes
- To describe the imaging features of complete collapse of the right or left lung on a chest radiograph and to list the appropriate causes of the collapse
- To distinguish lung collapse from massive pleural effusion on a frontal chest radiograph
- To recognise the halo sign and its association with a diagnosis of invasive aspergillosis in an immunosuppressed patient
- To describe the imaging features of bronchiectasis on chest radiographs and chest CT
- To describe the high-resolution CT (HRCT) signs of small airways disease and to differentiate between the direct signs (tree-in-bud, centrilobar changes) of exudative bronchiolitis and the indirect signs (mosaic pattern, air-trapping) of obliterative bronchiolitis (bronchiolitis obliterans)
- To describe the typical imaging patterns and basic clinical features of cystic fibrosis
- To describe the typical imaging patterns of tracheal and bronchial stenoses and to list the most common causes
- To describe the typical imaging patterns and basic clinical features of centrilobular emphysema on chest radiographs and CT
- To recognise a unilateral hyperlucent lung on chest radiographs or chest CT and to list an appropriate differential diagnosis
- To recognise the effects of various pathological processes on the component parts of the pulmonary lobule, as seen on high-resolution CT (HRCT)

- To describe the pathophysiology of the following imaging patterns:
  - » Ground glass opacity and lung consolidation
  - » Linear and reticular pattern
  - » Nodular pattern
  - » Honeycombing pattern
  - » Mosaic attenuation pattern
  - » Air-trapping
  - » Cysts and cyst-like structures
  - » Centrilobular opacities and tree-in-bud
  - » Crazy-paving pattern
- To describe the typical imaging features of thickening of the interlobular septa and the possible causes

SOLITARY AND MULTIPLE PULMONARY NODULES

- To describe the definitions of a solitary pulmonary nodule and a pulmonary mass
- To list the most common causes of a solitary pulmonary nodule, cavitary pulmonary nodules and multiple pulmonary nodules
- To describe the strategy for managing a solitary pulmonary nodule detected incidentally or at screening
- To have an in-depth understanding of the roles of contrast-enhanced CT and integrated PET/CT in the evaluation of a solitary pulmonary nodule
- To understand the features that indicate benignity of a solitary pulmonary nodule and their limitations
- To describe the complications of percutaneous lung biopsy and their frequency
- To describe the indications for chest tube placement as a treatment for pneumothorax related to percutaneous lung biopsy

BENIGN AND MALIGNANT NEOPLASMS OF THE LUNG

- To list the four major histological types of bronchogenic carcinoma, and the difference in treatment between non-small-cell and small-cell lung cancer
- To describe the current TNM classification for staging non-small-cell lung cancer, including the components of each stage
- To identify abnormal contralateral mediastinal shift on a post-pneumonectomy chest radiograph and to list two possible aetiologies for the abnormal shift
- To describe the acute and chronic radiographic and CT appearance of radiation injury in the thorax (lung, pleura, pericardium) and to identify the temporal relationship with radiation therapy
- To have an in-depth understanding of the roles of CT and MRI in lung cancer staging
- To describe the role of positron emission tomography (PET) and integrated PET/CT in lung cancer staging
- To describe the manifestations and the role of imaging in thoracic lymphoma
- To list the four most common extrathoracic metastatic sites for non-small-cell lung cancer and for small-cell lung cancer

THORACIC DISEASE IN IMMUNOCOMPETENT, IMMUNOCOMPROMISED AND POST-TRANSPLANT PATIENTS

- To describe the radiological manifestations of pulmonary mycobacterial infections on a radiograph and on CT
- To list the various types of pulmonary aspergillosis, to understand that they form part of a continuum and to recognise these entities on chest radiographs and chest CT
- To describe the major categories of disease-causing chest radiography or chest CT abnormalities in the immunocompromised patient
- To list two typical infections and two typical neoplasms in patients with AIDS and to describe the imaging features on chest radiography and chest CT
- To describe the typical imaging features and basic clinical features of Pneumocystis jiroveci pneumonia
- To list the three most important aetiologies of hilar and mediastinal adenopathy in patients with AIDS
- To describe the relevant differential diagnoses for widespread consolidation in an immunocompromised host
- To describe the typical imaging features and basic clinical features of post-transplant lymphoproliferative disorders
- To describe the typical imaging features and basic clinical features of graft-versus-host disease

CONGENITAL LUNG DISEASE

- To describe the typical imaging features and basic clinical features of pulmonary venolobar syndrome (scimitar syndrome)
- To describe the typical imaging features and basic clinical features of intralobar pulmonary sequestration and cystic adenomatoid malformation
- To describe the typical imaging features and basic clinical features of bronchial atresia on a chest radiograph and chest CT, and to list the most common lobes of the lungs in which it occurs

PULMONARY VASCULAR DISEASE

- To list five of the most common causes of pulmonary artery hypertension and to describe the typical signs on chest radiography and chest CT
- To understand the role of CT pulmonary angiography (CTPA), MRI/MRA and lower extremity venous studies in the evaluation of a patient with suspected venous thromboembolic disease, including the advantages and limitations of each test
- To describe the typical imaging features of enlarged pulmonary arteries on a chest radiograph and to distinguish them from enlarged hilar lymph nodes
- To describe the typical imaging features and basic clinical features of acute and chronic lobar and segmental pulmonary emboli on CT angiography
- To describe the typical imaging features of vascular redistribution seen in raised pulmonary venous pressure

AIRWAYS AND OBSTRUCTIVE LUNG DISEASE

- To describe the typical imaging features and basic clinical features of bronchiectasis
- To list the typical imaging features of air-trapping
- To describe the typical imaging features and basic clinical features of emphysema and the various patterns to include centrilobular, bullous and paraseptal emphysema
- To describe the typical imaging of tracheal abnormalities, including tracheomalacia, tracheal stenosis and tracheobronchomegaly

INTERSTITIAL LUNG DISEASE

- To describe the imaging patterns of interstitial lung disease on chest radiographs according to whether the pattern is predominantly in the upper, mid or lower zone; or shows central or peripheral predominance
- To describe typical imaging patterns of interstitial lung disease on chest radiographs including lung consolidation, ground glass opacities, nodular patterns, reticular patterns, cystic patterns and widespread septal lines
- To describe typical imaging patterns of interstitial lung disease on HRCT according to whether the pattern is predominantly in the upper, mid or lower zone; or shows perihilar or subpleural predominance; or shows a vascular or perivascular airway, a lymphatic or perilymphatic or an interstitial distribution
- To describe typical imaging patterns of interstitial lung disease on HRCT according to whether the pattern is fibrotic or non-fibrotic, predominantly septal thickening / nodularity, ground glass opacity, reticular pattern, honeycombing, nodular pattern, air space consolidation, tree-in-bud pattern, “crazy-paving” pattern, cyst and cyst-like pattern
- To know the main CT presentations of the most frequent interstitial lung disease (ILD; sarcoidosis, usual interstitial pneumonia, non-specific interstitial pneumonia, hypersensitivity pneumonitis)

PLEURA AND THE DIAPHRAGM

- To describe the typical appearance of pleural effusion on ultrasound, chest radiographs and CT
- To describe the typical imaging features of pneumothorax on upright and supine chest radiographs
- To describe the typical imaging features and basic clinical features of malignant mesothelioma
- To describe the imaging features related to heart failure including pleural effusions, vascular redistribution on erect chest radiographs, interstitial and alveolar oedema
- To define the terms “asbestos-related pleural disease” and “asbestosis”, and to describe the respective imaging findings
- To describe the imaging features and basic clinical features of progressive massive fibrosis and conglomerate masses secondary to silicosis and coal worker’s pneumoconiosis
- To describe the imaging features of various forms of pleural calcification on a chest radiograph or chest CT and its association with asbestos exposure, old TB, old empyema or old haemothorax
- To describe the imaging features of diffuse pleural thickening and to list four causes
- To describe the imaging features of split pleura sign in empyema

MEDIASTINAL AND HILAR DISEASE

- To list the most common causes of an anterior mediastinal mass and to confidently identify a mass in the anterior mediastinum on chest radiographs, chest CT and chest MRI
- To list the three most common causes of a middle mediastinal mass and to confidently identify a mass in the middle mediastinum on chest radiographs, chest CT and chest MRI
- To list the most common causes of a posterior mediastinal mass and to confidently identify a mass in the posterior mediastinum on chest radiographs, chest CT and chest MRI
- To list and describe the most common causes of bilateral hilar lymph node enlargement
- To list and describe the most common causes of "egg-shell" calcified lymph nodes in the chest
- To list and describe the most common causes of a mass arising in the thymus
- To describe the typical imaging features, basic clinical features and common associations of thymoma
- To list and describe the three types of malignant germ cell tumour of the mediastinum
- To describe the mechanisms and signs of pneumomediastinum
- To describe the imaging appearances of normal vessels or vascular abnormalities that may mimic a solid mass
- To describe the imaging features of mediastinal and hilar lymphadenopathy on chest radiographs, chest CT and chest MRI
- To describe the imaging signs of a benign cystic teratoma
- To describe the imaging signs of an intrathoracic thyroid mass
- To describe the imaging features of cystic mediastinal masses and to describe the differential diagnoses of a bronchogenic pericardial, thymic or oesophageal duplication cyst

THORACIC AORTA AND THE GREAT VESSELS

- To describe the significance of a right aortic arch with mirror image branching versus an aberrant subclavian artery
- To have an in-depth understanding of the advantages and disadvantages of CT, MRI/MRA and trans-oesophageal echocardiography in the evaluation of the thoracic aorta
- To define the terms "aneurysm" and "pseudoaneurysm" of the aorta
- To describe the imaging features and basic clinical features and to distinguish each of the following on chest CT and chest MRI: aortic aneurysm, aortic dissection, aortic intramural haematoma, penetrating atherosclerotic ulcer, ulcerated plaque, ruptured aortic aneurysm, sinus of Valsalva aneurysm, subclavian or brachiocephalic artery aneurysm, aortic coarctation, aortic pseudocoarctation and cervical aortic arch
- To describe the imaging features of the two standard types of right aortic arch and double aortic arch on chest radiographs, chest CT and chest MRI
- To describe the imaging features of an aberrant subclavian artery on chest CT
- To describe the imaging features seen in arteritis of the aorta on chest CT and chest MRI

CHEST TRAUMA

- To list three common causes of abnormal lung opacity following trauma on chest radiographs or chest CT
- To list the three most common causes of pneumomediastinum following trauma
- To describe the imaging features of a widened mediastinum on chest radiographs taken for trauma and to list the possible causes (including aortic / arterial injury, venous injury, fracture of sternum or spine)
- To describe the indirect and direct signs of aortic injury on contrast-enhanced chest CT

- To describe the imaging features and basic clinical features and to understand the significance of chronic traumatic pseudoaneurysm on chest radiographs, chest CT or chest MRI
- To describe the imaging features of fractured ribs, clavicle, spine and scapula on chest radiographs or chest CT
- To describe the imaging features of an abnormally positioned diaphragm or loss of definition of a diaphragm on chest radiographs following trauma and the association with a ruptured diaphragm
- To describe the imaging features of a pneumothorax and pneumomediastinum following trauma on chest radiographs
- To describe the imaging features of a cavitary lesion following trauma on chest radiographs or chest CT and to describe the association with laceration and pneumatocele formation, haematoma or abscess secondary to aspiration
- To describe the imaging features and to distinguish between pulmonary contusion, laceration and aspiration

POSTOPERATIVE CHEST

- To identify normal postoperative findings and complications of the following procedures on chest radiographs, chest CT and chest MRI:
  - Wedge resection mastectomy, lobectomy
  - Pneumonectomy
  - Coronary artery bypass graft surgery
  - Cardiac valve replacement
  - Aortic graft
  - Aortic stent
  - Transhiatal oesophagectomy
  - Lung transplant
  - Heart transplant
  - Lung volume reduction surgery

SKILLS

- To prepare a patient for chest CT including indication, venous access and beta-blocking
- To choose optimal acquisition parameters for chest CT
- To choose optimal post-processing tools for chest CT
- To manage procedural complications in the diagnosis and treatment of chest disease
- To design and optimize CT protocols and to adapt these protocols to evaluate each of the following, taking into account the patient's age:
  - Thoracic aorta and great vessels
  - Superior vena cava and brachiocephalic vein stenosis or obstruction
  - Pulmonary embolism
  - Diffuse lung disease
  - Tracheobronchial tree
  - Bronchiectasis
  - Small airway disease
  - Lung cancer staging
  - Oesophageal cancer staging
  - Superior sulcus tumour
  - Pulmonary metastases
  - Pulmonary nodule on a radiograph
  - Shortness of breath
  - Haemoptysis
- To confidently perform a radiological staging of bronchogenic cancer

- To perform the following imaging-guided transthoracic interventions under appropriate supervision, to understand the indications and contraindications, and to manage the complications:
  - Paracentesis and drainage of pleural effusions
  - Percutaneous lung biopsy
  - Paracentesis of mediastinal and pericardial fluid collections
  - Drainage of refractory lung abscess
- To apply inspiratory and expiratory imaging depending on the clinical indication
- To independently perform post-processing tasks for chest imaging studies, including multiplanar reformations (MPR), maximum intensity projections (MIP), minimum intensity projections (MinIP), volume rendering tools (VRT) and vessel analysis tools

COMPETENCES AND ATTITUDES

- To confidently justify diagnostic imaging examinations (including CT and MRI) and/or interventional procedures of the chest
- To confidently choose the best-suited method for evaluating disorders of the chest
- To communicate with the patient in order to obtain informed consent prior to diagnostic imaging and interventional procedures of the chest
- To choose optimal imaging protocols for radiographic, ultrasonographic, CT and MRI examinations of the chest
- To create and apply protocols and standard operating procedures to reduce exposure doses for radiological examinations of the chest
- To confidently supervise and teach technical staff to ensure that appropriate images are obtained for all radiological methods pertaining to chest imaging
- To confidently judge the quality of the imaging examinations in chest imaging and to devise strategies to improve image quality
- To confidently interpret and report chest CT for common clinical indications
- To interpret and report chest CT under supervision for rare clinical indications
- Making a specific diagnosis of interstitial lung disease (ILD) when HRCT appearances are characteristic
- To confidently interpret and report chest MRI for common clinical indications
- To interpret and report chest MRI under supervision for rare clinical indications
- To confidently report radiographic examinations of the chest for common and rare diseases
- To appreciate own limitations and to identify when it is appropriate to obtain assistance in interpreting and reporting images of the chest
- To confidently identify urgent and/or unexpected findings in imaging examinations of the chest and to communicate these timely and properly
- To communicate with patients and their relatives in order to explain their imaging findings of the chest
- To communicate with referring clinicians to discuss radiological findings of the chest
- To perform at multidisciplinary conferences and tumour boards for diseases of the chest