ESTI European Society of Thoracic Imaging

# ESTI 2015

JOINT MEETING OF ESTI AND THE FLEISCHNER SOCIETY

**JUNE 04-06, 2015**
BARCELONA, SPAIN

## FINAL PROGRAMME

Photo: © by Bengt Nyman

ESTI European Society of Thoracic Imaging

ESTI-Fleischner 2015

# WELCOME RECEPTION

## THURSDAY, JUNE 04, 18:00 AT THE GARDEN RESTAURANT NEXT TO THE FAIRMONT REY JUAN CARLOS HOTEL

The ECR GmbH/ESTI Office may not accept liability for personal injury, loss/damage to property, personal or otherwise belongings of participants and/or accompanying persons, either during or as a result of the evening event.



ESTI European Society of Thoracic Imaging

# ESTI-FLEISCHNER2015

## FINAL PROGRAMME

## CONTENTS

# GENERAL INFORMATION

### Congress Venue

Fairmont Rey Juan Carlos I
Av. Diagonal 661-671
08028 Barcelona, Spain

### Certificate of Attendance

The certificate of attendance/CME accreditation can be viewed and printed after the congress upon entering your ESTI MyUserArea at the website (www.myESTI.org). To enter your MyUserArea, please use your personal username and password.

### CME Credits

The "CT patterns of ILD and small airways disease" Hands-On course (June 03, 2015) is designated for a maximum of 3 European CME credits (ECMEC).
The Joint Meeting of ESTI and the Fleischner Society (June 04-06, 2015) is designated for a maximum of 17 European CME credits (ECMEC).

Continuing Medical Education (CME) is a programme of educational activities to guarantee the maintenance and upgrading of knowledge, skills and competence following completion of postgraduate training. CME is an ethical and moral obligation for each radiologist throughout his/her professional career, in order to maintain the highest possible professional standards. Each medical specialist should only claim those hours of credit that he/she actually spent in the educational activity.

### Conference Language

The meeting will be held in English. No simultaneous translation will be offered.

### Badge/Tickets

You are kindly asked to keep your badge visible on the congress grounds at all time. Pre-ordered evening event tickets will be handed out additionally to the congress badge. Evening event tickets may be purchased onsite at the registration desk upon availability.

### Onsite Congress Office

In case of any questions, kindly consult the ESTI registration desk, staff members will be happy to assist you.

| | |
|---|---|
| Wednesday, June 03 | 10:00 – 19:00 |
| Thursday, June 04 | 07:00 – 18:00 |
| Friday, June 05 | 07:30 – 18:00 |
| Saturday, June 06 | 08:00 – 17:00 |

### Onsite Registration Fees

| | |
|---|---|
| Regular Non Member | € 600.00 |
| Regular Member | € 450.00 |
| Junior Non Member | € 380.00 |
| Junior Member | € 300.00 |
| Technician Non Member | € 380.00 |
| Technician Member | € 290.00 |
| Fleischner Member | € 450.00 |
| Student | € 175.00 |
| Single Day Ticket | € 250.00 |
| Workshop Regular | € 115.00 |
| Workshop Junior | € 75.00 |

Registration fee for delegates includes:
- admittance to all scientific sessions
- admittance to the technical exhibition
- congress programme and abstracts
- certificate of attendance
- opening ceremony and welcome cocktail
- coffee breaks

Member Registration
Available for ESTI 2015 members in good standing.

Junior Registration
Available for juniors, young radiologists in training, under the age of 35. A proof of your junior status has to be shown at the registration desk.

Technician Registration
Available for technicians without any academic title. A proof of your technician status has to be shown at the registration desk.

Student Registration
Available for students under the age of 30. A proof of your student status has to be shown at the registration desk.

### Onsite Payment

Onsite payment can only be made by credit card (Visa or Euro/Mastercard) or in cash (Euro).
Please understand that no other payment facilities like cheques, etc. will be accepted.

### Name Changes

Name changes will be treated like the cancellation of the registration and a new registration of the other participant.

### Poster Exhibition – EPOS™

ESTI-Fleischner 2015 is using EPOS™, the Electronic Presentation Online System, the electronic format of the scientific exhibition developed by the European Congress of Radiology (ECR). EPOS™ offers a much greater flexibility than traditional scientific exhibits and provides better options for scientific communication.

### EPOS™ Area

Several workstations are available in the EPOS™ area (Marenostrum A) at which the current electronic exhibits can be viewed by the congress participants during the congress. All submitted posters will be accessible online after the congress via the ESTI website (www.myESTI.org).

### Media Centre

The media centre is located on the first level in room Marenostrum A. Trained staff will be available to assist you with the equipment. Speakers are reminded to check in at the media centre at least two hours prior to their scheduled session. Please note that the media centre should not be used to prepare your entire presentation and that due to the large number of speakers the workstations are only available for minor editing.

### Guideline for Speakers

- You are kindly requested to submit your presentation two hours before your session starts at the latest (USB sticks are recommended).
- All presentations have to be uploaded to the conference IT-system. No personal computer will be accepted for projection.
- Please be at the lecture room at the latest five minutes prior to the start of your session and identify yourself to the chairs.
- Kindly observe your presentation time. Exceeding the time limit will not be accepted and the chairpersons are requested to stop presentations in such cases.

### Future Meeting Desk

This area – located on the first level – offers you an overview of future meetings in the field of radiology and related disciplines, from all over the world. Feel free to contribute flyers and posters to promote your own meetings and courses.

### Coffee Breaks

Complimentary coffee and refreshments will be served during the official coffee breaks to all congress delegates.

### Industry Symposium Attendance

Attendees of any ESTI-Fleischner industry symposium agree that their registration details will be forwarded to the company organising that symposium. This agreement may be cancelled at any time by writing to the ESTI Office.

### Video/Audio

The participant acknowledges that lectures, presentations, speeches and other scientific events as well as the exhibition area and the reception area are filmed throughout the congress and that such film material is broadcasted by video and audio streaming and may also be used for other educational projects. The participation of delegates in such lectures, presentations, speeches and other scientific events as well as the presence of the participants in the exhibition area and the reception area therefore can be viewed at the ESTI website.

### Recording

Video- or audio-recording of any sessions or presentations is not allowed without the speaker's/organiser's prior written permission.

### Mobile Phones

Please do not forget to switch off your mobile phones before entering any of the lecture rooms.

### WIFI

Free WIFI is available in hotel rooms and the lobby.

### Film Panel Quiz

From June 04-06, there will be a monitor placed in the EPOS Area where participants can view/read 8 film panel cases. They can prepare the answers and hand them in at the registration desk until Saturday, June 06, 2015, 10:30. 3 Film Panel winners will be announced during the Awarding and Closing session on Saturday, June 06, 2015, from 15:10-15:30. Price is a free registration ticket to the ESTI 2016 Annual Scientific Meeting which will be held in Istanbul/TR, from May 26-28, 2016. Winners have to attend the awarding session in order to receive the price.

**Awards**

The following prices will be awarded on occasion of the Joint Meeting of ESTI and the Fleischner Society 2015:

Oral presentation
1x Magna Cum Laude
2x Cum Laude
2x Certificate of Merit

Poster presentation
1x Magna Cum Laude
2x Cum Laude
3x Certificate of Merit

**Safety**

The safety of all congress delegates and participants is of utmost importance to the ECR GmbH/ESTI. Security measures and precautions at the ECR GmbH/ESTI venue have been tightened to ensure maximum security for all attendees. Badges must be worn visibly on the congress grounds at all times. The ECR GmbH/ESTI reserves the right for staff to check participants' identification upon admission to and/or inside the congress venue. Participants may at any time be requested to present adequate proof of identity in the form of a passport, driver's license, national or military identification or student ID. Documents for the proof of identity must include a photograph and signature.

**Disclaimer/Liability**

ECR GmbH/ESTI cannot accept any liability for the acts of the suppliers to this meeting or the attendees' safety while travelling to or from the congress. All participants and accompanying persons are strongly advised to carry adequate travel and health insurance, as ECR GmbH/ESTI cannot accept liability for accidents or injuries that may occur. ECR GmbH/ESTI is not liable for personal injury and loss or damage of private property.

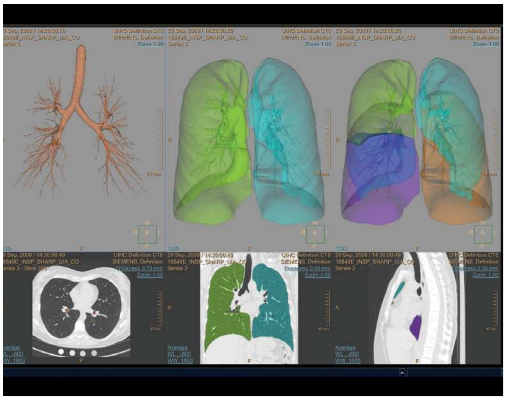

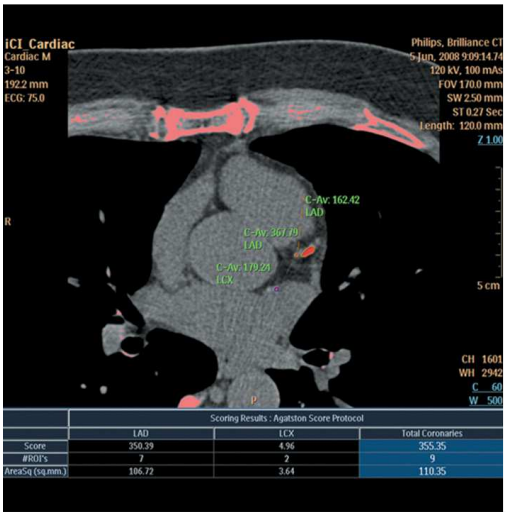


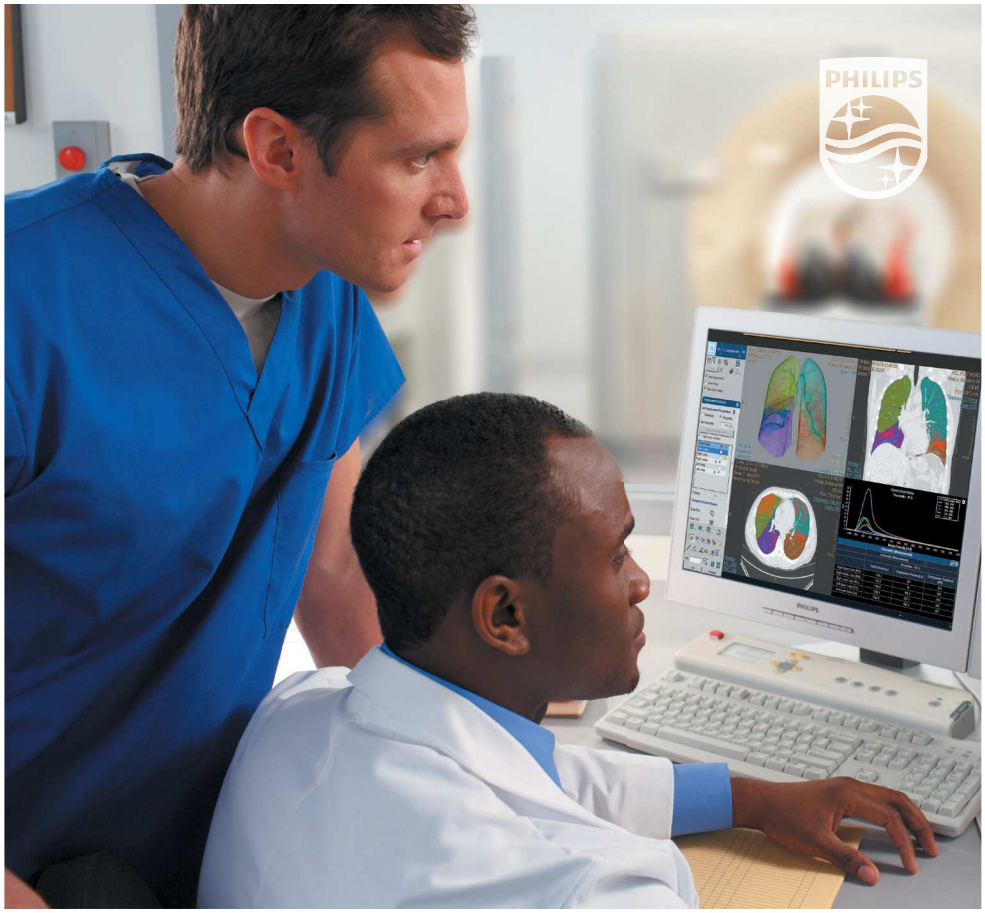


# Philips IntelliSpace Portal

## All your advanced analysis needs **one integrated solution**

Do you have the right tools to manage pulmonary patients?

**A comprehensive lung management solution on a single advanced platform.**

From nodule discovery to diagnosis to therapy monitoring and follow up, the IntelliSpace Portal offers a full suite of tools to help you track Pulmonary disease.

**Join the lunch symposium 'New insights in thoracic imaging, from acquisition to detection' on Friday, June 5 at 12:15.**

innovation you

Get more information at
**www.philips.com/intellispaceportal**

PHILIPS

# BARCELONA

Barcelona is the capital city of Spain and located on the coast between the mouths of the rivers Llobregat and Besòs and bounded to the west by the Serra de Collserola mountain range. Besieged several times during its history, Barcelona has a rich cultural heritage and is today an important cultural centre. Particularly renowned are the architectural works of Antoni Gaudí and Lluís Domènech i Montaner, which have been designated UNESCO World Heritage Sites.



# LIST OF SPONSORS

ESTI would like to thank all industry partners for their valuable support.

BRACCO
LIFE FROM INSIDE

PHILIPS

Riverain TECHNOLOGIES
See the Potential.

Roche

TMC

TERARECON

# EXHIBITION

The exhibition area is located on the first floor of the Fairmont Rey Juan Carlos I hotel.

Exhibition Opening Hours

| | |
|---|---|
| Thursday, June 04 | 08:30 – 18:00 |
| Friday, June 05 | 08:30 – 18:00 |
| Saturday, June 06 | 09:00 – 15:30 |

List of Exhibitors
- Bracco
- Philips
- Riverain Technologies
- Telemedicine Clinic
- TeraRecon



# FLOOR PLAN

# MEMBERSHIP INFORMATION



**Benefits of your ESTI Membership**

- Representation of thoracic imaging/radiology on a European level
- Reduced registration fees at the annual meetings of the society
- Personal ESTI account with access to Member's Directory
- Subscription to JTI – the Journal of Thoracic Imaging in your MyUserArea
- Research grants
- Educational material in thoracic imaging/radiology
- EPOS posters in your MyUserArea
- ESOR fellowship programme
- ESOR scholarship programme
- ESTI Newsletter
- Certificate of membership

**Membership Types & Fees**

| | |
|---|---|
| Full Member<br>Radiologists (not in training) with special interest and special experience in thoracic imaging, active within Europe or with a European nationality. | EUR 60.00 |
| Corresponding Member<br>Radiologists (not in training) with special interest and special experience in thoracic imaging, outside of Europe or with a non European nationality. | EUR 60.00 |
| Associate Member<br>Scientists or physicians active in fields related to thoracic radiology. | EUR 60.00 |
| Junior Member<br>Residents or physicians still in training until the age of 36 (excl. the age of 36). | EUR 30.00 |
| Senior Member<br>Former active members, who wish to maintain their membership after retiring. | EUR 30.00 |
| Full Member Reduced<br>Radiologists (not in training) with special interest and special experience in thoracic imaging who are active members of a national radiological society and active within Europe or with a European nationality. | EUR 48.00 |
| Junior Member Reduced<br>Residents or physicians still in training until the age of 36 (excl. the age of 36) who are active members of a national radiological society and active within Europe or with a European nationality. | EUR 24.00 |

Required proof(s)

The following membership types require one or more proofs:

- Junior Member (letter of your head of department confirming your junior status)
- Full Member Reduced (letter of your national radiological society confirming your national society member status)
- Junior Member Reduced (letter of your head of department confirming your junior status and letter of your national radiological society confirming your national society member status)

ESTI European Society of Thoracic Imaging

# GALA DINNER

## FRIDAY | JUNE 05, 2015 | 19:00
SALON TERRAL

**Meeting point: Salon Terral, 19:00**

Mezzanine floor, Rey Juan Carlos I hotel

Ticket price: € 50.00
Visit the registration desk to purchase your ticket(s).

# WELCOME FROM THE 2015 PRESIDENTS

On behalf of the European Society of Thoracic Imaging and the Fleischner Society, it is our great pleasure to invite you to participate in the **Joint Meeting of ESTI and the Fleischner Society 2015**. The meeting is to be held in the centre of Barcelona from June 04-06, 2015, at the Fairmont Hotel Rey Juan Carlos I.

Barcelona is the capital city of Spain and located on the coast between the mouths of the rivers Llobregat and Besòs and bounded to the west by the Serra de Collserola mountain range. Besieged several times during its history, Barcelona has a rich cultural heritage and is today an important cultural centre. Particularly renowned are the architectural works of Antoni Gaudí and Lluís Domènech i Montaner, which have been designated UNESCO World Heritage Sites.

The varied and interesting multidisciplinary programme is equally dedicated to most recent developments in thoracic imaging and diagnosis as well as to education and training.
This leading international congress in chest imaging 2015 is attracting different medical specialities beyond radiology as well as non-medical scientists and young academics. The multidisciplinary faculty of international experts will stimulate the academic discourse. Case-based discussions and interactive involvement of the audience guarantee practical applicability. Topics will be discussed from a clinical and radiological point of view, mirroring the growing importance of interdisciplinary cooperation. Renowned European and international speakers will share their knowledge and experience.

On Wednesday, June 03, a "CT patterns of ILD and small airways disease" Hands-On course will be offered with two parts, dedicated to pattern analysis and differential diagnosis. Both parts will be offered twice to allow a smaller audience and thus ensure an interactive approach.

A state-of-the-art technical exhibition will display the most recent technical developments in the area of thoracic imaging. Educational and scientific posters will be displayed on screens to allow discussions with colleagues and authors.

The congress is open to radiologists and clinicians actively involved or interested in thoracic imaging and diagnosis. Everybody is invited to participate and present the scientific work with awards awaiting the best papers and posters.

It is our great pleasure to invite you to join us in one of the most significant and exciting scientific events in the field of thoracic imaging in 2015, to take the opportunity to meet colleagues and friends, make new contacts, exchange knowledge and ideas and last but not least, enjoy Barcelona.

**We are looking forward to seeing you in Barcelona in June 2015!**

**Tomás Franquet**
ESTI President

**Hans-Ulrich Kauczor**
Fleischner Society President

# PROGRAMME OVERVIEW

## WEDNESDAY, JUNE 03, 2015 - HANDS-ON COURSE „CT PATTERNS OF ILD AND SMALL AIRWAYS DISEASE“

| Room 1 | Room 2 |
|---|---|
| 12:30-15:15<br>Part I | 12:30-15:15<br>Part II |
| 15:45-18:30<br>Part II | 15:45-18:30<br>Part I |

## THURSDAY, JUNE 04, 2015

| Room 1 | Room 2 |
|---|---|
| 08:30-09:40<br>Interstitial lung disease | 08:30-09:40<br>Vascular disease |
| 09:40-10:10<br>Opening Session and Honorary Lecture | |
| 10:30-12:10<br>Oncology: Pulmonary neuroendocrine proliferations and neoplasms | 10:30-12:10<br>Hemoptysis and aspiration: Multidisciplinary management |
| 12:20-13:20<br>Industry Symposium | |
| 13:30-15:30<br>ESTI meets SEICAT: Infections in the chest | 13:30-15:30<br>2015 update of chest CT protocols |
| 16:00-17:40<br>Novel techniques for imaging the thorax | 16:00-17:40<br>Lung cancer screening |

**Colour coding**

| | |
|---|---|
| Educational | |
| Scientific | |
| Educational Imaging | |
| Educational Clinical | |

## FRIDAY, JUNE 05, 2015

| Room 1 | Room 2 |
|---|---|
| 08:30-10:00<br>COPD and CF | 08:30-10:00<br>Pulmonary nodules and lung cancer |
| 10:30-12:00<br>Pulmonary embolism: Persistent controversies | 10:30-12:00<br>Current guidelines and recommendations |
| 12:15-13:15<br>Industry Symposium | |
| 13:30-15:30<br>Controversies in thoracic oncology | 13:30-15:30<br>Common pitfalls in ... |
| 16:00-17:40<br>Radiology beyond clinical imaging | 16:00-17:40<br>ESTI meets STR: Mediastinal tumours – An interactive session |

## SATURDAY, JUNE 06, 2015

| Room 1 | Room 2 |
|---|---|
| 09:00-10:15<br>ESTI meets ESCR: Assessing the heart on routine, ungated chest CT | 09:00-10:15<br>Thoracic interventions and cardiac imaging |
| 10:40-12:10<br>Film panel | |
| 12:10-13:30<br>Lunch Break | |
| 13:30-15:10<br>Diffuse lung diseases: New entities, new classifications | 13:30-15:10<br>Back to basics: The chest radiograph |
| 15:10-15:30<br>Awarding and Closing | |
| 15:45-16:30<br>General Assembly | |

# INVITED FACULTY

Alexander Bankier, Boston/US
Selen Bayraktaroglu, Izmir/TR
Catherine Beigelman-Aubry, Paris/CH
Jürgen Biederer, Gross-Gerau/DE
Phillip Boiselle, Boston/US
Lorenzo Bonomo, Rome/IT
Darren John Boone, Colchester/UK
Pierre-Yves Brillet, Bobigny/FR
Jose Caceres, Barcelona/ES
Eva Castaner, Sabadell/ES
Emmanuel Coche, Brussels/BE
Susan Copley, London/UK
Marco Das, Maastricht/NL
Sujal Desai, London/UK
Anand Devaraj, London/UK
Julien Dinkel, Heidelberg/DE
Jonathan Dodd, Dublin/IE
Gilbert Ferretti, Grenoble/FR
Marco Francone, Rome/IT
Tomás Franquet, Barcelona/ES
Thomas Frauenfelder, Zurich/CH
Benoit Ghaye, Brussels/BE
Ana Giménez, Barcelona/ES
Fergus Gleeson, Oxford/UK
Myrna Godoy, Houston/US
Jin Mo Goo, Seoul/KR
Lawrence Goodman, Milwaukee/US
Philippe Grenier, Paris/FR
David Hansell, London/UK
Thomas Hartman, Rochester/US
Ieneke Hartmann, Zwijndrecht/NL
Chris Haslett, Edinburgh/UK
Thomas Henzler, Mannheim/DE
Nigel Howarth, Chêne-Bougeries/CH
Takeshi Johkoh, Itami/JP
Nevzat Karabulut, Denizli/TR
Hans-Ulrich Kauczor, Heidelberg/DE
Talmadge King, San Francisco/US
Jeffrey Klein, Burlington/US
Anna Rita Larici, Rome/IT
Kyung Soo Lee, Seoul/KR
Ann Leung, Stanford/US
Diana Litmanovich, Boston/US
Christian Loewe, Vienna/AT
David Lynch, Denver/US
Heber MacMahon, Chicago/US
Edith Michelle Marom, Houston/US
Johanna Mayer, Heidelberg/DE
Theresa McLoud, Boston/US
Gustavo Meirelles, SaoPaulo/BR
Francesco Molinari, Tourcoing/FR
Arjun Nair, London/UK
John Newell, Iowa City/US
Mariaelena Occhipinti, Rome/IT
Yoshiharu Ohno, Kobe/JP
Anastasia Oikonomou, Toronto/CA
Simon Padley, London/UK
Anagha Parkar, Bergen/NO
Edward Patz, Durham/US
Anders Persson, Linköping/SE
Francois Pontana, Lille/FR
Charles Powell, New York/US
Mathias Prokop, Nijmegen/NL
Helmut Prosch, Vienna/AT
Martine Remy-Jardin, Lille/FR
Marie-Pierre Revel, Paris/FR
Santiago Enrique Rossi, Buenos Aires/AR
Geoffrey Rubin, Stanford/US
Jay Ryu, Rochester/US
Marcelo Sánchez, Barcelona/ES
Cornelia Schaefer-Prokop, Amersfoort/NL
Nicholas Screaton, Cambridge/UK
Joon Beom Seo, Seoul/KR
Mario Silva, Parma/IT
Eric Stern, Seattle/US
Nicola Sverzellati, Parma/IT
Denis Tack, Braine-L'Alleud/BE
Noriyuki Tomiyama, Suita/JP
Alfons Torrego, Barcelona/ES
Johny Verschakelen, Leuven/BE
Jose Vilar Samper, Valencia/ES
Charles White, Baltimore/US
Mark Wielpütz, Heidelberg/DE

# COURSE PROGRAMME WEDNESDAY, JUNE 03, 2015



## HANDS-ON COURSE „CT PATTERNS OF ILD AND SMALL AIRWAYS DISEASE“

### 12:30-15:15 Room 1

Group A | Part I

*Moderator: A. Oikonomou, Toronto/CA*

12:30 **Nodular pattern**
A. Giménez, Barcelona/ES

12:55 **Case-based nodular pattern**
G. Meirelles, SaoPaulo/BR

13:20 **Reticular pattern**
F. Molinari, Lille/FR

13:45 **Case-based reticular pattern**
I. Hartmann, Rotterdam/NL

14:10 **Increased density**
J. Dinkel, Munich/DE

14:35 **Traction bronchiectasis and honeycombing: Rad-Path correlation**
T. Johkoh, Itami/JP

15:00 **Questions**

### 12:30-15:15 Room 2

Group B | Part II

*Moderator: A.R. Larici, Rome/IT*

12:30 **Decreased density**
E. Stern, Seattle/US

12:55 **Case-based decreased density**
S. Copley, London/UK

13:20 **Case-based increased density**
T. Hartman, Rochester/US

13:45 **Small airways diseases**
S.E. Rossi, Buenos Aires/AR

14:10 **Case-based small airways diseases**
Ph. Boiselle, Boston/US

14:35 **Combined fibrosis and emphysema**
A. Nair, London/UK

15:00 **Questions**

**15:15-15:45 Break**

### 15:45-18:30 Room 1

Group A | Part II

*Moderator: N. Karabulut, Denizli/TR*

15:45 **Decreased density**
E. Stern, Seattle/US

16:10 **Case-based decreased density**
S. Copley, London/UK

16:35 **Case-based increased density**
T. Hartman, Rochester/US

17:00 **Small airways diseases**
S.E. Rossi, Buenos Aires/AR

17:25 **Case-based small airways diseases**
Ph. Boiselle, Boston/US

17:50 **Combined fibrosis and emphysema**
A. Nair, London/UK

18:15 **Questions**

### 15:45-18:30 Room 2

Group B | Part I

*Moderator: M. Wielpütz, Heidelberg/DE*

15:45 **Nodular pattern**
A. Giménez, Barcelona/ES

16:10 **Case-based nodular pattern**
G. Meirelles, SaoPaulo/BR

16:35 **Reticular pattern**
F. Molinari, Lille/FR

17:00 **Case-based reticular pattern**
I. Hartmann, Rotterdam/NL

17:25 **Increased density**
J. Dinkel, Munich/DE

17:50 **Traction bronchiectasis and honeycombing: Rad-Path correlation**
T. Johkoh, Itami/JP

18:15 **Questions**

# CONGRESS PROGRAMME THURSDAY, JUNE 04, 2015



## ROOM 1

**08:30-09:40 Interstitial lung disease** **Room 1**

*Moderator: S. Desai, London/UK*

08:30 Key note lecture
S. Desai, London/UK

08:36 Visual estimation/automated CALIPER quantitation and pulmonary function in idiopathic pulmonary fibrosis: Optimal prognostication
J. Jacob, London/UK

08:42 Visual estimation and automated CALIPER quantitation of disease in idiopathic pulmonary fibrosis: Validation against functional indices
J. Jacob, London/UK

08:48 Visual estimation and automated CALIPER quantitation of disease in idiopathic pulmonary fibrosis: A comparison and exploration of discordances
J. Jacob, London/UK

08:54 Quantitative MR for inflammatory activity assessment in nonspecific interstitial pneumonia
M. Buzan, Cluj-Napoca/RO

09:00 CT manifestations of chronic granulomatous disease in children
Q. Yao, Shanghai/CHN

09:06 Differences in forced vital capacity decline by extent of emphysema in patients with idiopathic pulmonary fibrosis and combined pulmonary fibrosis and emphysema syndrome
N. Sverzellati, Parma/IT

09:12 Imaging of portopulmonary venous anastomosis in portal hypertension: Venographic motion picture and overview of the literature
A. Sano, Osaka/JP

09:18 Value of clinical information in the evaluation of conventional antero-posterior chest X-rays in the ICU in comparison to chest CT as standard of reference – Analysis form a single
Th. Frauenfelder, Zurich/CH

09:24 Quantification of Pleural Effusions: Comparison of Sonography derived Measurements with segmentated Effusion-Volumes derived from Computed Tomography of the Thorax
T.D.L. Nguyen-Kim, Zurich/CH

09:30 Discussion

**09:40-10:10 Opening Session and Honorary Lecture** **Room 1**

09:40 Opening Lecture
T. Franquet, Barcelona/ES, H-U. Kauczor, Heidelberg/DE

09:50 Honorary Lecture „Imaging and prognostication of lung adenocarcinomas: From ground-glass opacity nodule and beyond“
K.S. Lee, Seoul/KR

**10:10-10:30 Coffee Break**

## ROOM 2

**08:30-09:40 Vascular disease** **Room 2**

*Moderator: A. Leung, Stanford/US*

08:30 Key note lecture
A. Leung, Stanford/US

08:36 **Predictive value of computed tomography in acute pulmonary embolism: Systematic review and meta-analysis**
F. Meinel, Munich/DE

08:42 **Dual phase CT Pulmonary Angiography in patients with suspected pulmonary hypertension: Impact of central pulmonary arterial size on flow related false positive (FP) diagnosis**
Ch. Sayer, London/UK

08:48 **Optimising CT Pulmonary Angiography (CTPA) – A prospective comparison of 3 techniques: Saline chaser, reduced kVP and high pitch spiral mode with free breathing**
Ch. Sayer, London/UK

08:54 **Reduced-dose dual-source coronary computed tomography angiography (CCTA): Is raw-data-based iterative reconstruction able to maintain diagnostic confidence?**
F. Pontana, Lille/FR

09:00 **Strict mandatory adherence to diagnostic protocol increases the yield of CTPA for pulmonary embolism**
S. Walen, Zwolle/NL

09:06 **High-pitch CTPA in 3rd generation dual-source CT: Feasibility in an unselected patient population**
B. Sabel, Munich/DE

09:12 **Diagnostic accuracy of unenhanced magnetic resonance imaging for pulmonary embolism diagnosis: A free-breathing True-Fisp sequence with 45 images for each anatomical position**
S. Nyren, Stockholm/SE

09:18 **Diffusion weighted imaging of the lung during free breathing; A feasibility study in acute pulmonary embolism in patients and healthy controls**
P. Lindholm, Stockholm/SE

09:24 **Cardiomyopathy: Diagnostic accuracy of standard Axial 64-Slice chest CT compared to dedicated cardiac image plane cardiac MRI**
D. Murphy, Dublin/IE

09:30 **Discussion**

**10:10-10:30 Coffee Break**

## ROOM 1

**10:30-12:10 Oncology: Pulmonary neuroendocrine proliferations and neoplasms** **Room 1**

*Moderator: I. Hartmann, Rotterdam/NL*

10:30 Advances in neuroendocrine lung tumour diagnosis
Ch. Powell, New York/US

10:55 CT features of DIPNECH
M-P. Revel, Paris/FR

11:20 Typical and atypical carcinoids
H. Prosch, Vienna/AT

11:45 Small cell lung cancer: An update
K.S. Lee, Seoul/KR

12:10-12:20 Break

**12:20-13:20 Industry Symposium – Evolving Needs in Thoracic CT: a Patient Centered Approach** **Room 1**

Advanced CT Technology in Thoracic Imaging: How to Minimize Patient Dose
M. Meyer, Mannheim/DE; Institute of Clinical Radiology and Nuclear Medicine, University Medical Center Mannheim, Germany

Tailoring CT Scans to Individual Patients: Theory and Validation
M. Prokop, Nijmegen/NL; Department of Radiology, Radboud University, Nijmegen Medical Center, Netherlands

13:20-13:30 Break

**13:30-15:30 ESTI meets SEICAT: Infections in the chest** **Room 1**

*Moderator: T. Franquet, Barcelona/ES*

13:30 Tuberculosis
E. Castaner, Sabadell/ES

14:00 Fungal infections
J. Mayer, Heidelberg/DE

14:30 Exacerbations in asthma and COPD
P.-Y. Brillet, Bobigny/FR

15:00 Pulmonary viral infections
M. Sanchez, Barcelona/ES

15:30-16:00 Coffee Break

**16:00-17:40 Novel techniques for imaging the thorax** **Room 1**

*Moderator: J. Dinkel, Munich/DE*

16:00 Evaluation of airway diseases: MRI and dual energy CT?
J. Biederer, Gross-Gerau/DE

16:25 PET and PET-CT
E. Patz, Durham/US

16:50 Dual energy and spectral CT: Current applications
M. Remy-Jardin, Lille/FR

17:15 Parametric response maps: A new clinical tool for lung imaging?
M. Silva, Parma/IT

## ROOM 2

| | | |
|---|---|---|
| **10:30-12:10** | **Hemoptysis and aspiration: Multidisciplinary management** | **Room 2** |
| | *Moderator: S.E. Rossi, Buenos Aires/AR* | |
| 10:30 | Bronchoscopic management and prevention of transbronchial biopsy bleeding<br>A. Torrego, Barcelona/ES | |
| 10:55 | CT imaging in patients with hemoptysis<br>S. Bayraktaroglu, Izmir/TR | |
| 11:20 | CT of large and small airways disease<br>D. Litmanovich, Boston/US | |
| 11:45 | The broadening spectrum of aspiration-related lung disease<br>J. Ryu, Rochester/US | |
| **13:30-15:30** | **2015 update of chest CT protocols** | **Room 2** |
| | *Moderator: J.B. Seo, Seoul/KR* | |
| 13:30 | CT evaluation of emphysema and airway diseases<br>Ph. Grenier, Paris/FR | |
| 14:00 | PE diagnosis: How to optimise pulmonary arterial enhancement<br>Th. Henzler, Mannheim/DE | |
| 14:30 | CT Protocols in Acute Aortic Syndromes<br>G. Rubin, Stanford/US | |
| 15:00 | Ultra low-dose CT: Myth or reality?<br>D. Tack, Braine-L'Alleud/BE | |
| **15:30-16:00** | **Coffee Break** | |
| **16:00-17:40** | **Lung cancer screening** | **Room 2** |
| | *Moderator: N. Karabulut, Denizli/TR* | |
| 16:00 | Role of CAD in detection and characterisation of lung nodules<br>M. Prokop, Nijmegen/NL | |
| 16:22 | Interval lung cancers: Definition and characteristics<br>J.M. Goo, Seoul/KR | |
| 16:44 | Nodule management: How to reduce false-positives?<br>A. Devaraj, London/UK | |
| 17:06 | Incidental findings: Which ones are relevant?<br>M. Godoy, Houston/US | |
| 17:30 | Discussion | |

# CONGRESS PROGRAMME FRIDAY, JUNE 05, 2015



## ROOM 1

| 08:30-10:00 | COPD and CF | Room 1 |
|---|---|---|
| | *Moderator: N. Sverzellati, Parma/IT* | |
| 08:30 | Key note lecture<br>N. Sverzellati, Parma/IT | |
| 08:40 | Correlation between quantitative computed tomography (CT) and pulmonary function tests in pulmonary emphysema – Comparison between two software tools<br>A. Poellinger, Berlin/DE | |
| 08:48 | Smoking-related emphysema: Longitudinal analysis from Italung-CT study<br>Ch. Romei, Pisa/IT | |
| 08:56 | Determination of the optimal level of iterative reconstruction on low dose CT for emphysema quantification in patients with COPD<br>S. Jansen, Dedemsvaart/NL | |
| 09:04 | Fully automated pulmonary lobar segmentation: Influence of different software programs onto quantitative evaluation of COPD<br>H-J. Lim, Heidelberg/DE | |
| 09:12 | CT airway morphology related to obesity: Evaluation pre and post bariatric surgery with functional correlation<br>N. Soneji, London/UK | |
| 09:20 | Lung morphology assessment of cystic fibrosis using PETRA sequence at 1.5 Tesla<br>G. Dournes, Bordeaux/FR | |
| 09:28 | Role of multidetector spiral CT in the preoperative evaluation of bronchopulmonary sequestration in children<br>X. Hu, Shanghai/CN | |
| 09:36 | The influence of inspiratory effort and emphysema on nodule volumetry reproducibility<br>J. Moser, London/UK | |
| 09:44 | Chest CT at a dose below 0.3 mSv: Impact of iterative reconstruction on image quality and lung analysis<br>S. Hajdu, Lausanne/CH | |
| 09:52 | Discussion | |

| 10:00-10:30 | Coffee Break |
|---|---|

## ROOM 2

| 08:30-10:00 | **Pulmonary nodules and lung cancer** | **Room 2** |
|---|---|---|
| | *Moderator: H. MacMahon, Chicago/US* | |
| 08:30 | Key note lecture<br>H. MacMahon, Chicago/US | |
| 08:40 | **Prevalence of pulmonary multi-nodularity in CT lung cancer screening**<br>R. Peters, Groningen/NL | |
| 08:48 | **Prevalence of pulmonary multi-nodularity in CT lung cancer screening and lung cancer probability**<br>R. Peters, Groningen/NL | |
| 08:56 | **Association of CT features and biomarkers (microRNAs) in early detection of lung cancer: Preliminary evaluation in asymptomatic smokers**<br>S. Calloni, Milan/IT | |
| 09:04 | **Radiologic characteristics of lung cancer detected with elevated serum CYFRA 21-1 level as a screening tool**<br>M.J. Cha, Seoul/KR | |
| 09:12 | **Prevalence and features of pleural abnormalities in lung cancer screening trial: Relation with asbestos exposure and risk of lung cancer**<br>M. Silva, Parma/IT | |
| 09:20 | **Clinicoradiologic and molecular study of 242 Non-Squamous Non-Small Cell Lung Cancer patients stratified by Thymidylated Synthase Expression Status**<br>S.W. Lee, Seoul/KR | |
| 09:28 | **Implementation of the Fleischner guidelines for solid and subsolid nodules; Results of a national survey**<br>A. Parkar, Bergen/NO | |
| 09:36 | **High awareness but limited compliance to Fleischner recommendations for the management of subsolid pulmonary nodules in clinical practice**<br>O. Mets, Utrecht/NL | |
| 09:44 | **A comparison of 4 different strategies for pulmonary nodule follow-up, applied to CT lung cancer screening: A per-nodule and per-subject analysis**<br>A. Nair, London/UK | |
| 09:52 | **Discussion** | |
| 10:00-10:30 | **Coffee Break** | |

## ROOM 1

**10:30-12:00 Pulmonary embolism: Persistent controversies** **Room 1**

*Moderator: M-P. Revel, Paris/FR*

10:30 Subsegmental PE: Diagnosis and management
C. Schaefer-Prokop, Amersfoort/NL

10:52 CT venography: When and how?
B. Ghaye, Brussels/BE

11:16 PE during pregnancy: How to optimise CT angiography?
A. Leung, Stanford/US

11:38 Incidental PE discovered during cancer follow-up CT
A. Parkar, Bergen/NO

12:00-12:15 Break

**12:15-13:15 Industry Symposium** **Room 1**

Advances and perspectives in lung cancer imaging using multi-slice computed tomography
E. Coche, Brussels/BE

CT for Pulmonary Embolism (PE): New insight from acquisition to detection
Ch. White, Baltimore/US

13:15-13:30 Break

**13:30-15:30 Controversies in thoracic oncology** **Room 1**

*Moderator: M. Silva, Parma/IT*

13:30 Current knowledge on tumour induction by computed tomography
A.R. Larici, Rome/IT

13:58 Indolent lung cancer: A new entity?
J.M. Goo, Seoul/KR

14:26 Non surgical and surgical approaches for NSCLC
F. Gleeson, Oxford/UK

14:54 Imaging follow-up modalities after surgery for NSCLC
Y. Ohno, Kobe/JP

15:22 Discussion

15:30-16:00 Coffee Break

**16:00-17:40 Radiology beyond clinical imaging** **Room 1**

*Moderator: Th. Frauenfelder, Zurich/CH*

16:00 Structured reporting
Th. McLoud, Boston/US

16:25 Multidisciplinary conferences
J. Verschakelen, Leuven/BE

16:50 Publishing in imaging journals
N. Karabulut, Denizli/TR

17:15 How to avoid Bias in imaging studies
D.J. Boone, Colchester/UK

## ROOM 2

| | | |
|---|---|---|
| **10:30-12:00** | **Current guidelines and recommendations** | **Room 2** |
| | *Moderator: L. Goodman, Milwaukee/US* | |
| 10:30 | Guidelines for nodule management: Theory and practice<br>A. Bankier, Boston/US | |
| 10:52 | Fleischner Society guidelines for solid and subsolid nodules<br>H. MacMahon, Chicago/US | |
| 11:16 | Guidelines for lung cancer screening: Differences between countries and continents<br>L. Bonomo, Rome/IT | |
| 11:38 | Fibrosing lung diseases 2015<br>N. Sverzellati, Parma/IT | |

| | | |
|---|---|---|
| **13:30-15:30** | **Common pitfalls in ...** | **Room 2** |
| | *Moderator: E. Castaner, Sabadell/ES* | |
| 13:30 | Lung nodule diagnosis: Common pitfalls<br>E. Coche, Brussels/BE | |
| 14:00 | Pulmonary embolism diagnosis<br>N. Screaton, Cambridge/UK | |
| 14:30 | Pleural plaque diagnosis<br>C. Beigelman-Aubry, Lausanne/CH | |
| 15:00 | Interstitial lung disease<br>D. Lynch, Denver/US | |

| | |
|---|---|
| **15:30-16:00** | **Coffee Break** |

| | | |
|---|---|---|
| **16:00-17:40** | **ESTI meets STR: Mediastinal tumours – An interactive session** | **Room 2** |
| | *Moderator: E. Stern, Seattle/US* | |
| 16:00 | Tumours of the anterior mediastinum<br>E.M. Marom, Houston/US | |
| 16:25 | Tumours of the posterior mediastinum<br>M. Occhipinti, Rome/IT | |
| 16:50 | Tumours of the middle mediastinum<br>Ch. White, Baltimore/US | |
| 17:15 | How and when to perform CT biopsy for mediastinal lesions<br>J. Klein, Burlington/US | |

# CONGRESS PROGRAMME SATURDAY, JUNE 06, 2015



## ROOM 1

**09:00-10:15 ESTI meets ESCR: Assessing the heart on routine, ungated chest CT — Room 1**

*Moderator: D. Litmanovich, Boston/US*

09:00 **Reporting cardiac findings on chest CT**
Ch. Loewe, Vienna/AT

09:18 **What to say about the coronary arteries?**
S. Padley, London/UK

09:36 **Fatty images of the heart**
M. Francone, Rome/IT

09:54 **Cardiac tumours: Diagnosis and differentials**
F. Pontana, Lille/FR

**10:15-10:40 Coffee Break**

**10:40-12:10 Film panel — Room 1**

*Moderators: A. Persson, Linköping/SE; N. Tomiyama, Suita/JP*

**Team 1 ESTI:**
M. Das, Maastricht/NL; Th. Frauenfelder, Zurich/CH; N. Screaton, Cambridge/UK; M. Wielpütz, Heidelberg/DE

**Team 2 Fleischner:**
M. Prokop, Nijmegen/NL; Th. McLoud, Boston/US ; J. Newell, Iowa City/US; J.B. Seo, Seoul/KR

**12:10-13:30 Lunch Break**

**13:30-15:10 Diffuse lung diseases: New entities, new classifications — Room 1**

*Moderator: D. Lynch, Denver/US*

13:30 **Pleuroparenchymal fibroelastosis**
S. Desai, London/UK

13:55 **Molecular imaging in diffuse lung disease**
Ch. Haslett, Edinburgh/UK

14:20 **IPF – Novel treatment options**
T. King, San Francisco/US

14:45 **ILD: Imaging in pharmacological trials**
D. Hansell, London/UK

**15:10-15:30 Awarding and Closing — Room 1**

*T. Franquet, Barcelona/ES; H-U. Kauczor, Heidelberg/DE*

**15:30-15:45 Break**

**15:45-16:30 General Assembly — Room 1**

## ROOM 2

| 09:00-10:15 | **Thoracic interventions and cardiac imaging** | **Room 2** |
|---|---|---|
| | *Moderator: F. Gleeson, Oxford/UK* | |
| 09:00 | Key note lecture<br>F. Gleeson, Oxford/UK | |
| 09:10 | How often does anatomical fat appear to be pleuro-pulmonary disease in the lateral view?<br>A. Villanueva Marcos, Cambridgeshire/UK | |
| 09:16 | Role of CT perfusion in the evaluation of the response to Radiofrequency Thermal Ablation in patients treated for lung cancer<br>P. Franchi, Rome/IT | |
| 09:22 | CT angiography coronary findings in young patients with no risk factors after an ischemic event and stent placement. What´s beyond the conventional angiography<br>M. Navarro Fernandez-Hidalgo, Madrid/ES | |
| 09:28 | The value of cardiac MR in the diagnosis of left ventricular non-compaction cardiomyopahty<br>T. Willems, Groningen/NL | |
| 09:34 | Cardiac MRI characterization of Phospholamban R14del-related cardiomyopathy<br>T. Willems, Groningen/NL | |
| 09:40 | Detection of myocardial edema in acute myocarditis: Semiquantitative low and high b value evaluation<br>J. Broncano, Cordoba/ES | |
| 09:46 | Patient risk score for pulmonary biopsy: How to choose the correct needle<br>R. Iezzi, Rome/IT | |
| 09:52 | Image-guided thoracic biopsy in the younger population – A 5 year retrospective review of histology proven thoracic disease in 11-35 year olds<br>Th. Semple, London/UK | |
| 09:58 | CT-Wire-guided VATS small pulmonary nodule removal is a safe and reliable procedure; Evaluation of 130 consecutive cases<br>R. Wolf, Groningen/NL | |
| 10:04 | Discussion | |

| 10:15-10:40 | **Coffee Break** |
|---|---|

| 13:30-15:10 | **Back to basics: The chest radiograph** | **Room 2** |
|---|---|---|
| | *Moderator: J. Dodd, Dublin/IE* | |
| 13:30 | The Chest X-ray: Is it obsolete?<br>L. Goodman, Milwaukee/US | |
| 13:50 | The chest radiograph: Lung parenchyma<br>G. Ferretti, Grenoble/FR | |
| 14:10 | The azygos system<br>J. Caceres, Barcelona/ES | |
| 14:30 | Common pitfalls in chest x ray diagnosis<br>J. Vilar Samper, Valencia/ES | |
| 14:50 | Missed lung cancer<br>N. Howarth, Chêne-Bougeries/CH | |

# INVITED ABSTRACTS



## Honorary Lecture - Imaging and prognostication of lung adenocarcinomas: From ground-glass opacity nodule and beyond

*K.S. Lee; Seoul/KR*

### Body

The persistent presence of pure ground-glass nodules (GGNs) in the lungs on thin-section CT leads to making a diagnosis of neoplastic condition that has an excellent prognosis. Approximately 80% of persistent pulmonary GGNs represent histopathologically pre-invasive (AAH and AIS), minimally invasive, or invasive lung adenocarcinomas. The nodules show slow growth over time with volume doubling time of more than > 400 days. As the nodule size, volume, and the nodule mass of GGNs increase physically, there appear histopathologically multi-focal areas of invasive component within background of predominantly lepidic growth pattern. Thus, invasive components of MIA or invasive adenocarcinoma may appear histopathologically when nodules are still in pure GGO state prior to the appearance of solid component on HRCT. When GGNs are 15 mm or more in diameter with a high nodule mass or high attenuation (mean attenuation, > -472 HU) or harbor a solid component within them, the nodules have more chance of being invasive adenocarcinomas (ADCs). When the GGNS are small, the nodules are usually pre-invasive (AAH and AIS) or MIA and followed-up CT study is recommended until they reach 15 mm in diameter or until the patient with the nodule is 70 years or more in age. The follow-up interval may be usually annual or biennial. Surgical resection is given when the GGNs are 15 mm (presumed cut-off point between MIA and invasive adenocarcinoma) or more in diameter. The surgical approach is wide wedge resection or segmentectomy (sublobar resection) with secured resection margin of > 10 mm or > 1 of a margin to tumor ratio. Lymph node dissection is not usually performed. Such a surgical approach (sublobar resection without lymph node dissection) may be applicable to pure GGNs of < 20 mm. Management methods may be the same to multiple pure GGNs, under the stipulation that each nodule has its own identity (not lung to lung metastases). Multiple wedge resection or chemotherapy may be considered for multiple GGNs (Lee HY et al. *AJR Am J Roentgenol* 2014;202:W224-W233).
For part-sold or solid solitary pulmonary nodular (SPN) lung ADCs, pathologic scoring system using the newly proposed lung adenocarcinoma classification scheme (grading the two most predominant histologic subtypes of the carcinoma) appears to help predict patient survival in SPN lung adenocarcinoma and shows close correlation with imaging biomarker studies. Because imaging biomarker study results are closely correlated with pathologic score and thus enable one to predict patient survival, the preoperative evaluation of tumor malignancy degree using PET/CT or CT may allow one to determine to do further staging workup and to select appropriate therapeutic strategies for patients with small lung adenocarcinoma (Lee HY et al. *Radiology* 2012;264:884-893).
For advanced-stage lung ADCs or recurrent tumors, prognostication could be performed in consideration of both biologic tumor behavior (tumor spread pathways) and tumor genomics. Imaging tumor behaviors (radiophenotypes) may be stratified into five groups: 1) pleuropericardial seeding, 2) a mass with lymph node (LN) metastasis, 3) a mass with miliary or lymphangitic metastasis, 4) extrathoracic metastasis, and 5) mixed type. EGFR mutation and ALK rearrangement tests are performed routinely by acquiring tissue samples suitable for molecular analyses. When recurrent, a half of the patients with lung ADC and EGFR+ show extrathoracic metastasis-pattern, and patients with ALK+ disease show a tendency to have a large tumor burden, but longer progression-free survival (PFS) particularly with crizotinib therapy. With recurrence, pleuropericardial seeding type is related to longer PFS after second-line treatment (EGFR-TKIs or crizotinib). Genomic-feature analysis is associated with CT radiophenotype at the time of recurrence or treatment failure and may help predict patient prognosis after target therapy. Accordingly, radiophenotypic analysis and characterization for tumor biology assessment is needed along with a genomic study for optimizing patients' stratification for their treatment and prognosis prediction (Yoon HJ et al. *Clin Lung Cancer*, submitted).

## CT features of DIPNECH

*M.-P. Revel[1], G. Chassagnon[2]; [1]Paris/FR, [2]Tours/FR*

### Body

DIPNECH (Diffuse Idiopathic Pulmonary NeuroEndocrine Cell Hyperplasia) is defined as the proliferation of pulmonary neuroendocrine cells (PNECs), not crossing the basal membrane, in patients without predisposing conditions such as smoking or chronic lung diseases.
Proliferation of the PNECs leads to airway wall thickening and eventually small airways obliteration. When nodular proliferations of PNECs extend beyond the basement membrane, proliferation is termed tumorlet if less than 5 mm in diameter or carcinoid tumor, if more than 5 mm. DIPNECH preferentially affects women (89%) with a mean age of 58 years. Forty-seven to 55% of patients with DIPNECH are symptomatic presenting respiratory manifestations as non-productive cough, dyspnea and wheezing. The remaining patients are asymptomatic.
DIPNECH must be suspected on CT when signs of small airways disease such as mosaic perfusion are associated with numerous small nodules and fewer larger nodules, respectively representing tumorlets and carcinoids. Bronchial wall thickening and other bronchial abnormalities such as mucoid impactions and bronchectasis are seen in approximately 20% of patients. Expiratory CT showing air trapping is useful when inspiratory CT is normal.
Post processing such as Minimum Intensity Projection is very useful and allows for a better depiction of mosaic perfusion, whereas MIP helps detection of small nodules. In asymptomatic patients who are incidentally found to present with numerous nodules on CT, the main differential diagnosis is lung metastasis. Knowledge of this often underdiagnosed disease is important for patient management.

*Coronal minimum intensity projection image showing mosaic perfusion*

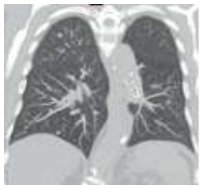

*Coronal maximum intensity projection image showing numerous small nodules*

### Take Home Points

- DIPNECH preferentially affects middle-age women and is asymptomatic in half of them
- Bronchial wall thickening and mucoid impaction are present in 20% of the patients
- Mosaic perfusion is due to neuroendocrine cell proliferation within the small airways walls
- Numerous small nodules are usually detected on CT and should not be taken for lung metastasis
- The combination of mosaic perfusion and numerous small nodules is very suggestive of the diagnosis

## Typical and atypical carcinoids

*H. Prosch; Vienna/AT*

### Body

Pulmonary carcinoid tumors are neuroendocrine neoplasms, which comprise less than 5% of all lung cancers. Based on their histological characteristic pulmonary carcinoids are categorized as typical carcinoids, which represent 80-90% of all pulmonary carcinoids, and atypical carcinoids. As compared to typical carcinoids, atypical carcinoids are characterized by a higher malignant potential and thus a worse prognosis.
As most of the pulmonary carcinoids are located in close anatomical relationship to central bronchi, their symptoms are caused by obstruction and comprise asthma-like symptoms, hemoptysis and post-obstructive pneumonitis. In rare cases, pulmonary carcinoids may be hormonally active leading to a carcinoid syndrome.
At CT, central carcinoid tumors appear as well-defined, well-enhancing nodules or masses arising from a main bronchus or a lobar bronchus, frequently leading to bronchial narrowing. This in turn may lead to air-trapping, mucous plugging, atelectasis or post-obstructive pneumonitis. Peripheral carcinoids appear as well-defined lobulated nodules and may also be associated with air-trapping, atelectasis or bronchiectasis. Up to 30% of all carcinoids may show some calcifications.

### Take Home Points

- Pulmonary carcinoids comprise typical and atypical carcinoids and are rare tumors with a mostly good prognosis
- Pulmonary carcinoids most frequently present as well defined and well-enhancing nodules or masses which may or may not be calcified
- Most carcinoids arise from the central airways and thus may lead to distal air-trapping, mucous plugging, atelectasis or post-obstructive pneumonitis

## Small cell lung cancer: An update

*K.S. Lee; Seoul/KR*

### Body

The cells in small cell lung cancers (SCLCs) are usually small and round or fusiform in shape on pathology. Also, SCLCs have high cellularity with a very high mitotic rate. Therefore, the prognosis and tumor biology of these neuroendocrine (NE) tumors worsen as the grade of malignancy increases

Most SCLCs are located centrally and appear with mediastinal (92%) or hilar (84%) lymphadenopathy with the displacement or narrowing of the tracheobronchial trees (68%) or major vessels (68%). Other intra-thoracic CT findings are major (at least lobar) atelectasis (30%), a noncontiguous parenchymal mass (41%), and pleural effusion (38%). In 5% to 10% of cases, SCLC manifests as a peripheral nodule without associated lymphadenopathy. Intratumoral calcification may be seen in up to 23% of SCLCs.

SCLC is usually classified using a two-stage system, i.e., limited (LD) or extensive disease (ED). LD is defined as a tumor confined to one hemithorax including regional mediastinal and supraclavicular lymph nodes, whereas ED is defined as disease beyond these boundaries. The criteria for these two categories remain controversial. However, the Veterans Administration Lung Study Group (VALG) definition of LD, primary tumor and nodal involvement limited to one hemithorax, is widely used. Differently, Jhun and his colleagues suggested that the UICC 7th TNM staging system can contribute to a more precise prognosis in patients with SCLC (1). Further prospective validation studies are required to confirm the applicability of this TNM staging system to SCLC in clinical practice.

In cases of SCLCs, the tumors showed high FDG uptake with their SUVs ranging from 6.1 to 17.3 (mean, 11.6; median, 11.7). The maximum SUV appears to be related to the patients' survival. Chong et al. (2) found a significant negative correlation between the initial maximum SUVs of SCLCs and patients' survival. For example, a maximum SUV greater than 13.7 suggests relatively shorter survival time for patients with SCLC. Pandit et al. (3) reported that PET of patients with SCLC is useful for predicting prognosis, especially among treated patients. After-treatment survival in PET-positive cases is significantly worse than in PET-negative cases.

Accurate staging is important for patients with a SCLC. Patients with limited disease are treated with chemoradiation therapy, whereas those with extensive disease usually receive chemotherapy alone. PET has been considered valuable for initial tumor staging and for treatment planning of SCLC. Stage evaluation using PET is accurate and it usually concurs with the final clinical stage determined by conventional methods.

### References

Jhun BW, Lee K-J, Jeon K, et al. Clinical applicability of staging small cell lung cancer according to the seventh edition of the TNM staging system. *Lung Cancer* 2013;81:65-70

Chong S, Lee KS, Kim BT, et al. Integrated PET/CT of pulmonary neuroendocrine tumors: diagnostic and prognostic implications. AJR Am J Roentgenol 2007;188:1223-1231

Pandit N, Gonen M, Krug L, Larson SM. Prognostic value of [18F]FDG-PET imaging in small cell lung cancer. *Eur J Nucl Med Mol Imaging* 2003;30:78-84

## Bronchoscopic management and prevention of transbronchial biopsy bleeding

*A. Torrego; Barcelona/ES*

### Body

Transbronchial lung biopsy (TBLB) is required for evaluation of some patients with pulmonary infiltrates secondary to interstitial lung disease (ILD), neoplasm or some infections. The diagnostic success of histopathologic assessment is variable, and affected by such factors as specimen size, experience, presence of crush artefact, biopsy technique and pre-test predictive value.
Either with forceps or cryoprobes, pneumothorax and especially severe bleeding are the most important complications associated with TBLB as well as other bronchoscopic procedures such as needle aspiration or bronchial brushing.
In addition, bleeding risk depends on several factors. There are factors related to the procedure (cryoprobe, bigger forceps) or the patient (comorbidities, coagulation disorders, platelets abnormalities).
Preparation for a possible bleeding is very important before performing any bronchoscopy. Both, pharmacological and non-pharmacological treatments (bronchial blockers, etc) need to be prepared and checked before the procedure. Management of an endobrochial severe bleeding is probably the most difficult situation for any bronchoscopist. When bleeding happens, the primary goal must be to ensure open airway to avoid asphyxia as well as different techniques to reduce or stop the haemorrhage. Some of these techniques will be expose during the presentation.

### Take Home Points

- Severe bleeding is the most important potential complication of transbronchial lung biopsy
- Risk factors are related to the patient and the procedure
- Prevention, preparation and management are important to reduce risk

## CT imaging in patients with hemoptysis

*S. Bayraktaroglu; Izmir/TR*

### Body

Hemoptysis can be a life threatening respiratory emergency. The most common causes of hemoptysis are bronchectasis, infections such as tuberculosis and fungal infections, chronic bronchitis and malignancies. The imaging modalities used in evaluation of hemoptysis are Chest Radiography, Computed Tomography (CT), Conventional Angiography – Bronchial Artery Embolization.
Computed Tomography is a rapid, noninvasive tool that helps in accurate assesment of site and cause of bleeding. Multidetector CT (MDCT) angiography is widely used in the setting of major or massive hemoptysis. MDCT has the capability to image a wide anatomical range in a single breath hold. Contrast-enhanced MDCT produces high-resolution angiographic images with a combination of multiplanar reformatted images . MDCT angiography permits evaluation of the origin and course of abnormal bronchial arteries and enlarged non-bronchial systemic arteries that may be the cause of hemoptysis.
In a patient with hemoptysis it is important to assess the pulmonary parenchyma, the airway and the mediastinum. The most frequent signs of bleeding in the pulmonary parenchyma are centrilobular nodules, ground glass opacities and consolidations. These findings help to localize the site of bleeding. Possible underlying causes of hemoptysis can also be detected on CT scans such as bronchiectasis , lung carcinoma, acute and chronic lung infections (such as tuberculosis and aspergillosis).
Assesment of thoracic vasculature is also important. It must include the bronchial and nonbronchial systemic arteries and the pulmonary arteries. The bronchial arteries are the most common source of bleeding in hemoptysis. Bronchial arteries most commonly arise directly from the descending aorta at the T5 and T6 levels of the vertebral bodies. They appear as enhancing nodular or linear structures within the mediastinum and around the central airway. Bronchial arteries with a diameter of 2 mm are considered to be abnormal and are candidates for embolisation therapy. In addition to bronchial arteries, chronic inflammatory processes recruit collateral blood supply from nonbronchial arteries via transpleural vessels and Nonbronchial systemic arteries (NBSA) may be a source of hemoptysis in such cases. NBSA arise from branches of the supraaortic great vessels (brachiocephalic artery,subclavian arteries, thyrocervical and costocervical trunks), the

axillary arteries, the internal mammary arteries and infradiaphragmatic branches from the inferior phrenic arteries. At contrast-enhanced CT, they usually appear along pleural surfaces as abnormally dilated arteries. Although the systemic arterial system is the primary source of bleeding in hemoptysis, bleeding may result from a pulmonary arterial source. The pulmonary arteries must be checked to exclude the possibility of pulmonary emboli. The pulmonary arteries may also be the source of hemorrhage in cases of direct invasion by neoplastic disease or by infectious diseases such as tuberculosis (Rasmussen aneurysms). The pulmonary AVMs, pulmonary artery aneurysms associated with vasculitis (Behcet's Disease) are other rare causes of bleeding related with pulmonary arteries.

### Take Home Points

Initial radiologic evaluation of patients with hemoptysis includes a chest radiograph. The contrast enhanced MDCT has an important role in detection of site and cause of bleeding. Performing an angio-MDCT helps in assesment of thoracic vasculature including the bronchial and nonbronchial systemic arteries and the pulmonary arteries. MDCT prior to embolization or surgery helps in management of the patient.

## CT of large and small airways disease

*D. Litmanovich; Boston/US*

### Body

The presentation will focus on small and large airways anatomy, most common airway diseases with focus on COPD and trachebronchomalacia, stressing radiological-pathological correlation. Advanced imaging such as dynamic CT and MR of the airways will be discussed. Currently available methods for radiation dose optimization for complexe airway MDCT examinations will be discussed.

### Take Home Points

1. Both static and dynamic imaging are required for assessment of large and small airways
2. MRI can contribute to airway imaging
3. Familiarity with specific appearance of common and uncommon airway pathology is essential for precise diagnosis

## The broadening spectrum of aspiration-related lung disease

*J. Ryu; Rochester/US*

### Body

Aspiration syndromes such as airway obstruction from an inhaled foreign body, aspiration pneumonitis, and aspiration pneumonia are well-recognized. In recent years, however, it has become apparent that the spectrum of aspiration-related pulmonary syndromes is broader and much more varied in clinical and radiologic presentation. The type of syndrome resulting from aspiration depends on the quantity and nature of the aspirated material, chronicity, and host responses. These aspiration-related syndromes can be categorized into airway disorders including vocal cord dysfunction, large airway obstruction with a foreign body, bronchiectasis, bronchoconstriction, and diffuse aspiration bronchiolitis; and parenchymal disorders including aspiration pneumonitis, aspiration pneumonia and exogenous lipoid pneumonia. In idiopathic pulmonary fibrosis, aspiration has been implicated in disease progression and acute exacerbation. Aspiration may increase the risk of bronchiolitis obliterans syndrome in patients with lung transplants. Aspiration is most likely to occur in subjects with decreased level of consciousness, compromised airway defense mechanisms, dysphagia, gastroesophageal reflux, and recurrent vomiting. Accumulating evidence suggests that a causative role for aspiration is often unsuspected in patients presenting with aspiration-related pulmonary diseases; thus, many cases go undiagnosed. In this session, the broadening spectrum of these pulmonary syndromes with a focus on presenting features and diagnostic aspects will be discussed.

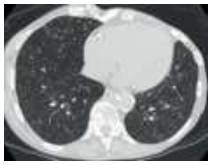

*Diffuse aspiration bronchiolitis*

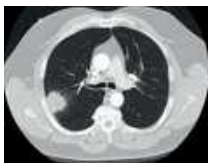

*Aspiration-related lung mass*

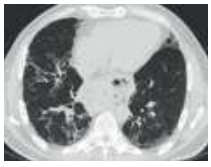

*Aspiration and usual interstitial pneumonia (UIP)*

### Take Home Points

Aspiration is associated with a spectrum of pulmonary syndromes beyond aspiration pneumonia and aspiration pneumonitis. Aspiration-related syndromes can be categorized into airway disorders including vocal cord dysfunction, large airway obstruction with a foreign body, bronchiectasis, bronchoconstriction, and diffuse aspiration bronchiolitis; and parenchymal disorders including aspiration pneumonitis, aspiration pneumonia and exogenous lipoid pneumonia. Aspiration has been implicated in progression of disease and acute exacerbation seen in idipathic pulmonary fibrosis (IPF). Aspiration may increase the risk of bronchiolitis obliterans syndrome in patients with lung transplant

## Tuberculosis

*E. Castañer; Sabadell/ES*

### Body

Pulmonary tuberculosis (TB) remains a common worldwide infection that produces high mortality and morbidity, especially in developing countries. In 2013, an estimated 9.0 million (360 000 of whom were HIV-positive) people developed TB and 1.5 million died from the disease.
Chest radiographs play a major role in the screening, diagnosis, and response to treatment of patients with TB. However, the radiographs may be normal or show only mild or nonspecific findings in patients with active disease.
We will review the chest radiograph findings of TB, which vary widely in function of several host factors, age, prior exposure to TB, and underlying immune status.
CT is a useful tool, in detecting TB incidentally, in resolving cases with inconclusive findings on chest radiographs, and in assessing disease activity. Centrilobular nodules and tree-in-bud appearance are the most common CT findings of active pulmonary tuberculosis.
Worldwide, an estimated 3.5% of new and 20.5% of previously treated TB patients had multidrug-resistant tuberculosis (MDR-TB) and 9.0% of patients with MDR-TB had extensively drug resistant TB (XDR-TB). The radiologic findings of MDR-TB and XDR-TB are similar to those of TB; however, the multiresistant types tend to have more extensive consolidation and tree-in-bud appearance.
We discuss some of the thoracic complications, including aspergilloma, superimposed distress, cystic lesions, and Rasmussen aneurysm.
To finish we will talk about nontuberculous mycobacteria (NTM). Mycobacterium avium complex (MAC) is the most common cause of NTM pulmonary disease. NTM can resemble tuberculous infection. The classic form typically affects elderly men with underlying disease. The upper lobe distribution is most common, usually with cavitary disease and centrilobular nodules. The nonclassic form (Lady Windermere syndrome) typically affects elderly white women without underlying disease; it commonly presents with cylindrical bronchiectasis and centrilobular nodules more frequently found in the lingula and middle lobes.

### Take Home Points

The clinical and radiologic features of tuberculosis may mimic those of many other diseases so the knowledge of the widening spectrum of radiologic findings is of paramount importance.
CT is a useful tool, in resolving cases with inconclusive findings on chest radiographs, and in assessing disease activity.

## Fungal infections

*J. Mayer; Heidelberg/DE*

### Body

Opportunistic infections including invasive fungal infections (IFI) are the leading cause of morbidity and mortality in severely immunocompromised patients despite of successful prophylaxis and empirical therapy. The incidence of invasive fungal infections ranges from 10 to 30% in patients with acute myeloid leukemia (AML), high risk acute lymphoblastic leukemia (ALL), recurrent leukemia and allogeneic hematopoietic stem cell transplantation (HSCT). Incidence rates in patients with lymphoma, solid tumors treated with conventional or high dose chemotherapy followed by autologous stem cell rescue (autologous HSCT) are lower and mostly

below 5%. Hematopoietic stem cell transplantation is a common therapeutic procedure in treatment of a diseases such as relapse of acute leukemia, bone marrow failure syndromes, and primary immunodeficiencies. In relation to hematopoietic stem cell transplantation, the patients suffer neutropenia, delayed T cell response (often until one year), acute or chronic graft versus host disease (GVHD) and iatrogenic immunosuppression for GVHD control.
The diagnosis of invasive fungal diseases in immunocompromised patients is based on clinical, radiological and microbiological findings, and there is a consensus definition of possible, probable and proven invasive fungal disease by the European Organization for Research and Treatment in Cancer and Mycosis Study Group (EORTC/MSG). For example, this has been demonstrated for β-D-glucan, which is a mycological criterion for IFI. The current recommended imaging modality in immunocompromised adults has changed from conventional radiography to computed tomography: CT has a higher sensitivity (detection of minimal infiltrates due to low immune response in severely immunocompromised patients) and a better possibility to characterize infiltrates and possible underlying agent.

### Take Home Points

Early chest CT imaging in immunocompromised patients suspected of having invasive fungal pneumonia can help identify disease early, leading to improved outcome.

## Exacerbations in asthma and COPD

*P.-Y. Brillet; Bobigny/FR*

### Body

Exacerbations in asthma and COPD are characterized by worsening of respiratory symptoms beyond normal day to day variations and requiring change in medications. These severe conditions may lead to hospital admission and are potentially "life threatening".
In COPD, exacerbations can be precipated by several factors, with infections (viral or bacterial) as the most common causes. Conditions that may mimic and/or aggravate exacerbation need to be ruled out, including pulmonary embolism, cardiac failure or pleural disease. Exacerbations can be observed more frequently in specific COPD phenotypes (with increased bronchial thickening on quantitative computed tomography) and in patients with pulmonary hypertension.
In asthma, exacerbations occur more frequently in severe disease, but can also been observed in controlled asthma. It can be precipated by external agents (infection, pollution) or poor adherence to medications.
In asthma, the clinical question is focused on specific conditions associated to severe asthma (allergic bronchopulmonary aspergillosis, vasculitis...) and differential diagnoses.

### Take Home Points

- In exacerbations of COPD, CT can be indicated to rule out pneumonia and other conditions, including pulmonary embolism or pleural disease
- At CT, increased bronchial thickening, bronchial secretions and bronchiolar micronodules can be observed in case of exacerbations of COPD. Consolidations are signs of pneumonic exacerbations.
- In asthma, CT may be required to rule out specific conditions associated to severe asthma (allergic bronchopulmonary aspergillosis, vasculitis ...) and differential diagnoses

## Pulmonary viral infections

*M. Sanchez; Barcelona/ES*

### Body

The incidence of viral pneumonia is underestimated. Every year about 200 million cases of viral community-acquired pneumonia occur: 100 million in children and 100 million in adults. In adults, viruses are causative agents in a third of cases of community-acquired pneumonia. Numerous viruses, including influenza virus, measles virus, Hantavirus, adenovirus, herpesviruses, varicella-zoster virus, cytomegalovirus, and Epstein-Barr virus, can cause lower respiratory tract infection in adults. In children, respiratory syncytial virus, rhinovirus, human metapneumovirus, human bocavirus, and parainfluenza viruses are the agents identified

most frequently. In adults viral pneumonia can be classified into two clinical groups: atypical pneumonia in healthy hosts and viral pneumonia in immunocompromised hosts.
In immunosuppressed patients with cough, dyspnea, chest pain, and fever a HRCT should be performed in cases of negative, equivocal, or nonspecific chest radiograph.
HRCT findings in viral pneumonia include small poorly defined centrilobular nodules and patchy, often bilateral, areas of peribronchial ground-glass opacity and consolidation. Air trapping may be present because of associated bronchiolitis. Interlobular septal thickening, bronchial wall thickening, and tree-in-bud opacities may also be present. Advanced viral pneumonia with diffuse alveolar damage is characterized by patchy or confluent consolidation and ground-glass opacities. Imaging and clinical manifestations of viral pneumonia are nonspecific and do not predict its origin. Clinical relevant information are patient age, immune status, community outbreaks, symptom onset and duration, and presence of a rash. In the appropriate clinical setting the HRCT findings can suggest the diagnosis of viral infection.

### Take Home Points

- To know the most relevant pulmonary viral infections.
- To show the HRCT findings in viral pneumonia.
- To emphasize the usefulness of HRCT in patients with neutropenic fever and normal Chest x-ray

## CT evaluation of emphysema and airway diseases

*Ph. Grenier; Paris/FR*

### Body

In COPD patients, chest CT protocols have to be optimized for both visual assessment and quantitative analysis of airway and lung disease. Thin collimation MDCT acquisition without contrast enhancement over the entire lung, in a single breath hold at suspended full inspiration allows to obtain voxels having almost cubic dimensions. This permits to obtain multiplanar reformations of high quality. This protocol facilitates the identification of the predominant morphologic findings and their grouping into different subtypes including emphysema, airway disease and associated features. CT quantitative analysis of emphysema and airway disease has been developed to get better phenotyping and to assess progression of disease overtime.

### Quantitative CT (QCT) measurement of emphysema

It correlates better with macroscopic measurements of emphysema than visual scoring. The commonly used metric is the percentage of lung voxels with CT attenuation below a threshold value. Using thin collimation MDCT, the highest correlation between QCT metrics and histology was found when CT threshold for measuring the percentage of low attenuation (%LAA) is set at – 960 / – 970 HU. However in the interest of balancing between sensitivity and specificity the threshold of – 950 HU is now commonly used. An alternative approach is to use the density of a percentile of the CT attenuation of histogram. Although histologic correlation has shown that the optimal percentile value for this determination is the 1st percentile, most studies have used the 15th percentile because of concern regarding the presence of noise and artefacts at the 1$^{st}$ percentile. The quantitative analysis of emphysema may be done as a whole or at a regional or lobar level.

*Sources of variations in measurement of emphysema* have to be minimized.

1- There are differences in emphysema measurements at varying inspiratory levels, but this may not be clinically relevant above 90% of vital capacity. As a result, the use of spirometric control of lung volume is not necessary but carefully coaching of the patient by the technologist is important to achieve total lung capacity.
2- Because differences in reconstruction algorithms have a large effect in CT measurements of low attenuation areas, a smooth reconstruction algorithm is generally used.
3- Several studies reported that dose reduction (down to 50 mAs) can be applied without clinical importance, but other did found a significant difference in QCT measurement between high dose and low dose.
4- When multiple scanners are involved, scans can be corrected by calibrating for tracheal air.
5- Smoking status should always be taken into account when assessing the severity of emphysema at QCT. Actually current smokers appear to have lower levels of emphysema compared with former smokers, and the extent of emphysema appears to increase quite rapidly after smoking cessation, reflecting a fall in lung attenuation (inflammatory cells in lung results in partial averaging that mask the areas of low attenuation).

*CT is able to detect progression of emphysema.* Percentage of emphysema on the follow up scan may be corrected using the achieved lung volume on the baseline scan. This can reduce the variability in emphysema quantification by a factor 2. CT density (15$^{th}$ percentile) was found to be more sensitive as an index of progression compared with physiology or health status.

### QCT of gas trapping

Gas trapping severity may be quantified on expiratory CT as the percentage of lung voxels with CT attenuation less than – 856 HU or – 850 HU with excellent correlations with predictive FEV1% and FEV1/FEVC ratio. Other potential measures include expiratory to inspiratory ratio of mean lung density, and change in relative lung volume with attenuation values from – 860 HU to – 950 HU between paired inspiratory and expiratory scan. The latter metric offers the advantage to extract emphysema from the volume of interest in order to assess the severity of gas trapping in non emphysematous lung. Most recently, non rigid registration of inspiratory and expiratory scans has allowed for an assessment of voxel-by-voxel density change and directional strain patterns. Despite the use of these deformable registration techniques that provide ventilation maps, QCT analysis of gas trapping on low dose CT show important variation on repeat CT scans, regardless of lung volume correction or reproducible breath hold.

### QCT of airway dimensions

It may be obtained by morphometric analysis of airways in MDCT. 3D airway lumen segmentation, lumen caliber analysis, central axis interaction and cross section morphometric analysis after 2D segmentation of the airway lumen and walls performed on each multiplanar reformatted image. Metrics on any bronchus include luminal diameter, area or volume, bronchial wall thickness area or volume and relative measures (% of bronchial wall area). Commonly used measure of bronchial wall area is the square root of wall area of a hypothetical bronchus of internal perimeter of 10 mm, calculated from linear regression of all measured bronchi (ideally 4 to 6th generation). Such QCT measurement of subsegmental airway dimensions can provide an estimate of small airway remodelling in COPD. In COPD patients, bronchial wall thickening is an important independent predictor of airflow limitation and risk of acute exacerbation. However QCT analysis of airway dimension is suffering from sources of variation that include the airway algorithm, size of the airway (6th generation), partial volume averaging, resolution of CT scans, lung volume (inspiration level), body mass index and field of view (voxel size). CT radiation dose has to be maintained in the range of up to 200 mAs. Some investigators found no influence of radiation dose on accuracy of their algorithm in low dose CT scan at 50 mAs. Iterative reconstructions algorithm does not influence QCT measures. Evidence of the effect of lung volume on QCT of airway dimension is lacking. Variability between CT measurements may be substantial, especially in small bronchi.
*QCT analysis of airways has also been used for phenotyping asthma.* Assessment of gas trapping extent and measurement of bronchial lumen and wall volumes provide clusters of patients that differ in terms of disease severity. In severe asthma, quantitative CT analysis of airways may assess architectural remodelling throughout the bronchial tree. Airway narrowing tends to give a characteristic dead-tree appearance of the central axis of the trancheobronchial tree, with decrease of the complexity of airway branching. Increased airway wall area and percent of wall airway area and presence of multiple bronchial stenoses are also biomarkers of severe disease in asthma.

### Take Home Points

1. Optimized protocols for thin collimation MDCT of the chest allows to measure the different disease components in COPD and to identify markers of disease severity in uncontrolled asthmatics
2. QCT is able to assess progression of emphysema.
3. Standardization of methods for assessing small airway dysfunction and airway remodelling has to be defined and interscan variability estimated before the evaluation of outcomes after intervention.

## PE diagnosis: How to optimise pulmonary arterial enhancement

*Th. Henzler; Mannheim/DE*

### Body

Pulmonary embolism (PE) is a very common and potentially life-threatening disease depending on the presence of right ventricular dysfunction. Over the last 15 years, multi-detector CT pulmonary angiography (CTPA) has become the imaging modality of choice for the detection of PE particularly as the de facto first line imaging test in patients with suspected acute PE. However, the diagnostic accuracy of CTPA studies highly depends on high vessel attenuation, a sufficient contrast-to-noise ratio (CNR) as well as the presence of motion artifacts especially for the assessment of segmental and subsegmental PE. Moreover, PE is a frequent unsuspected finding in CT staging examinations that are technically not performed as dedicated CTPA studies in terms of contrast administration and bolus timing. The aim of the presentation is to provide an overview about currently available state-of-the-art CTPA acquisition techniques as well as image-post processing methods that help to optimize arterial vessel enhancement including low kVp imaging, dual-enegy CT with monochromatic reconstructions as well as high pitch acquisition techniques.

### Take Home Points

- Physical background on the value of low kVp tube voltage settings
- Background of dual-energy based monoenergetic low keV reconstructions
- Optimal contrast injection techniques for CTPA studies

## CT Protocols for Acute Aortic Syndromes

*G. Rubin; Durham/US*

### Body

The accurate detection and evaluation of acute aortic syndrome is one of the radiologist's most important and immediately impactful opportunities to improve human health. Acute aortic syndrome is often a clinical emergency and a situation that demands accurate radiologic diagnosis and intervention to provide lifesaving care. The diagnosis of acute aortic syndrome has evolved significantly over the last two decades, evolving from an arteriographic diagnosis to a diagnosis based upon multi-detector row CT angiography.
Collectively, acute aortic syndromes represent life-threatening conditions that are associated with a high risk of aortic rupture and sudden death. The typical presentation is the sudden onset of chest pain, which may be accompanied by signs, or symptoms of hypoperfusion or ischemia to distal organs, extremities, or brain. Traditionally, acute aortic syndromes are categorized as aortic dissection, intramural hematoma, and penetrating atherosclerotic ulcer, but rupturing thoracic aortic aneurysms also belong in this differential diagnosis.
High quality and comprehensive aortic and end-organ assessment should be performed using multi-detector row CT with at least 16 detector rows. This scanner configuration allows for imaging from the neck through the pelvis, acquiring ≤ 1.5 mm thick transverse sections during the arterial phase of enhancement from an intravenous contrast administration. It also allows for the use of electrocardiographic gating of the scan when appropriate, as described below.
An unenhanced scan can be valuable prior to the administration of intravenous contrast for the detection of what can be subtle intramural and periaortic blood. It can also be useful for mapping the specific regions of the aorta that are abnormal and thus guide the mode of subsequent CT angiographic acquisition. While an associated increase in radiation exposure results from this approach, the potential value of the information almost always outweighs the risk. It has been hypothesized that using dual energy scanning, a virtual unenhanced scan might obviate the need for a separate unenhanced acquisition. However, this approach has not been comprehensively validated in acute aortic syndromes, and it eliminates the possibility of using the preliminary unenhanced acquisition to guide the decision to gate the CT angiogram.

While unenhanced imaging can reveal aortic dilation, intramural and extra-aortic hemorrhage, and in uncommon circumstances directly visualize an intimal flap, the use of intravenously administered contrast medium is required for a complete assessment in suspected acute aortic syndrome. The volume and flow rate of the contrast material should be adjusted based on patient size. A concentrated iodine solution of ≥ 350mg of iodine/ml should be used in order to assure adequate intravenous delivery of iodine with a safe and reliable flow rate of the contrast material into the peripheral vein. Typical volumes and injector flow rates for iodinated contrast range between 60 and 115 ml at flow rates between 3.5 and 6 ml/sec.
To assure diagnostic aortic enhancement throughout the CT acquisition, the duration of the contrast injection should exceed the scan duration by five to ten seconds, and the initiation of the CT angiographic acquisition should be based upon the active monitoring on the arrival of iodine within the descending thoracic aorta.
Because of the likelihood of direct extension of thoracic aortic disease into the abdominal aorta and iliac arteries, unrelated but important abdominal aortoiliac pathology, the value of assessing the caliber of a transfemoral delivery route to intra-aortic repair devices, and the possibility for abdominal visceral ischemia, scan ranges that extend through the abdomen and pelvis are highly recommended as a routine approach to imaging acute aortic syndromes. By beginning the scan in the neck and extending inferiorly below the lesser trochanters of the femurs, the scan range will comfortably include several centimeters of the cervical carotid arteries through the bifurcation of the femoral artery. Scan ranges that include less anatomy risk the possibility that important observations will be missed, and additional CT scans with further injections of iodinated contrast material may be required.
When the ascending aorta is involved with an acute aortic syndrome, electrocardiographic (ECG) gating can be valuable. ECG gating allows for clear delineation of the position of the intimal flap across the cardiac period, distinction of the involvement of the structures of the aortic root including the coronary artery ostia and the aortic annulus, elimination of pulsation related artifacts that can blur the aortic wall, and subtle regions of extravasation. Unlike the use of ECG gating in the setting of coronary artery disease assessment, the strategy for using ECG gating in acute aortic syndromes does not rely upon the manipulation of heart rate or coronary artery dimension using beta-blockers or nitrates. Regardless of the basal heart rate, the placement of ECG leads and acquisition of a retrospectively gated CT scan (with judicious use of ECG directed x-ray tube current pulsing to minimize radiation exposure) allows for a four-dimensional assessment of the aortic root, aortic valve, coronary arteries and ascending aorta. It is sufficient to reconstruct 10 phases every 10 percent of the R-R interval. Gating is only beneficial through the thoracic aorta. The abdomen and pelvis is acquired after the chest using a non-gated acquisition with minimization of delay between the two scans so that only one contrast injection is required.
Recently, dual energy techniques have become widely available on CT scanners. Investigators have considered the use of "virtual unenhanced" scans created from the CT angiogram as a method for eliminating a separate unenhanced scan. While dual energy techniques can be used to bring about overall radiation dose savings through the use of lower beam energies, data are insufficient to support the replacement of a dedicated unenhanced scan with a virtual unenhanced scan.

### Take Home Points

Thin section unenhanced CT coupled with contrast-enhanced CT angiography is central to the effective diagnosis and characterization of acute aortic syndromes.
ECG gating is a critical element for assessing the aortic root and extension of disease into the coronary arteries.
Extension of the scan range into the abdomen and pelvis often uncovers critical abnormalities of the abdominal aortoiliac system and its branches.

## Ultra low-dose CT: Myth or reality?

*D. Tack; Braine-L'Alleud/BE*

### Body

The purposes of this lecture are to explain and illustrate
- How to quantify the tube output in CT and radiography.
- How to take the "in patients variability" of dose measurements into account.
- How to convert tube outputs into effective dose.
- Comparisons between CT and radiography with the newest available techniques.
- The lack of appropriateness of frequently used terms qualifying CT dose.
- A reasonable and humble approach to dose description to address the question "Ultra low-dose CT: Myth or reality".

### Take Home Points

Substantial improvement of CT techniques are required to lower the radiation dose delivered by CT close to that delivered by radiographic examinations for thorax examinations.

## Evaluation of airway diseases: MRI and dual energy CT?

*J. Biederer; Gross-Gerau/DE*

### Body

Imaging of airways and their diseases plays an increasing role for scientific investigation and clinical monitoring. More specific therapeutic approaches e.g. in chronic obstructive lung disease or cystic fibrosis have raised the need for following local alterations of lung morphology and function beyond the scope of global tests such as spirometry – in particular for small airways that contribute only little to total airway resistance and thus can hide a significant amount of disease from conventional pulmonary function tests. Despite their differences in etiology and pathophysiology, airway diseases have common radiological manifestations. Computed tomography (CT) is typically the technique of choice to study diffuse diseases and small airways involvement with high spatial resolution, but this only with a not negligible amount of radiation exposure. Magnetic resonance imaging (MRI) is increasingly used as an alternative, since it offers radiation free imaging for young subjects or for scientific use, but at the cost of lower spatial resolution.
In healthy subjects, high resolution computed tomography (CT) depicts peripheral airways down to the 8$^{th}$ generation while magnetic resonance imaging (MRI) only allows for direct visualization of airways in excess of 2-3 mm in diameter (first sub-segmental level or 4th generation). Airway dysfunction such as collapse in expiration can be directly visualized with dynamic CT (trachea to segmental level) or MRI (trachea to lobar level). Dedicated software for the quantification of airway pathology is only available for CT so far. Even smaller airways can become visible on CT and MRI, when altered by bronchiectasis and wall thickening or by intrinsic contrast enhancement, e.g.retained mucus in cystic fibrosis patients. Dysfunction (i.e. expiratory collapse or occlusion) of smaller airways can become visible as mosaic pattern or air trapping on expiratory scans as indirect signs of bronchiolar involvement(CT and MRI).
More differentiated functional imaging is achieved with contrast enhancement. Intravenous application of a contrast bolus can show perfusion deficits due to airway obstruction and hypoxic vasoconstriction as an indirect functional test. Dual energy CT (DECT) and dynamic contrast enhanced MRI (DCE-MRI) are both capable to show these effects in clinical use. Direct visualization of ventilated airspace can be achieved with DECT and Xenon- (alternatively Krypton) inhalation or with MRI and hyperpolarized noble gases (3He, 129Xe), however, both technologies are usually not readily available for clinical imaging. Sophisticated technologies such as Fourier decomposition MRI for non-contrast enhanced ventilation-/perfusion-weighted image are in development.

### Take Home Points

- Airways are directly visualized to the 8th (CT) and 4th order (MRI)
- bronchiectasis and mucous plugging increase the visibility of small airways
- mosaic perfusion and air trapping are signs of bronchiolar involvement
- perfusion deficits after i.v.-contrast reflect hypoxic vasoconstriction in ventilation disorders (CT, MRI)
- inhaled Xenon (DECT) and hyperpolarized noble gases (MRI) directly visualize pulmonary airspace

## PET and PET-CT

*E. Patz; Durham/US*

### Body

PET-CT imaging in the chest has become an important diagnostic tool in the evaluation of thoracic abnormalities. Its primary role is for tumor imaging as it helps differentiate benign from malignant nodules, stage lung cancer, predict response to therapy, and follow patients after treatment is complete.
PET-CT has also been used for non-oncologic diseases, but the indications are less well defined. PET is a fundamental component of the molecular imaging initiative, and as new more specific imaging probes and better instrumentation are developed, PET-CT is certain to improve diagnostic accuracy and become even more integrated into clinical practice.

### Take Home Points

- FDG-PET/CT is an invaluable component in evaluate thoracic disease.
- Primary focus of PET-CT is in oncology: differentiating benign from malignant nodules, staging lung cancer, and following treatment response.
- Potentially novel imaging probes may improve specificity.

## Dual energy and spectral CT: Current applications

*M. Remy-Jardin, J.-B. Faivre, J. Remy; Lille/FR*

### Body

The basic principle of spectral (dual-energy) CT imaging is the acquisition of two datasets from the same anatomic location with use of two different kilovolt peaks, usually 80 and 140 kVp. The clinical applications of spectral imaging can be considered in two main directions. The first application is based on the possibility of generating additional information to routine diagnostic imaging. The best known application is the creation of maps of lung perfusion, also described as "perfusion" scans, first applied in the field of acute pulmonary embolism. More recently, ventilation imaging has emerged as another potential option while virtual non contrast imaging, substracting the iodine from an original contrast-enhanced image, is mainly used to avoid repeated scans. In the second application, one can consider replacing single-energy CT, i.e., the current standard scanning mode, by dual-energy CT in order to take advantage of virtual monochromatic spectral imaging. The justifications for this new concept are twofold. First, virtual monochromatic imaging can ensure an optimal image quality for each and every examination. Second, dual-energy monochromatic images may facilitate iodine load reduction at CT pulmonary angiography. The emerging applications of dual-energy CT in the field of oncology will also be described.

### Take Home Points

- There are various applications for dual-energy CT in clinical practice.
- There is no dose penalty with judicious use of dual-energy CT techniques
- There are two conditions for dual-energy implementation in daily practice:
  (1) to become familiar with the technique;
  (2) to demysthify the perceived complexity to workflow.

## Parametric response maps: A new clinical tool for lung imaging?

*M. Silva; Parma/IT*

### Body

Parametric response map (PRM) is a method for quantitative analysis of volumetric imaging, such as magnetic resonance (MR) and computed tomography (CT). PRM quantifies tissue changes by means of voxel-wise co-registration between datasets in different temporal and/or functional state.
PRM was first used for early assessment of tumor response to chemotherapy, by serial brain MR in glioma. It was therefore translated to other fields for oncological (e.g. head and neck, breast, liver, prostate, and bone) or functional purpose (bone, lung).
Quantitative analyses of pulmonary imaging started since the 80s, when correlation was proven between histologic emphysema and low attenuation areas (LAA) on inspiratory CT. Later on, characterization of small airway disease was also evaluated by means of expiratory CT. Quantitative differentiation between emphysema and small airway disease was proposed by techniques based on mean lung density or varying whole-lung density thresholds in inspiration and expiration. Otherwise, PRM analyses inspiratory (Figure 1) and expiratory (Figure 2) co-registered CT and provides detailed characterization of emphysema and air trapping, on a voxel basis (Figure 3). Therefore, this detailed quantitative techniques allows for apportioning of diverse pulmonary abnormalities also in case of heterogeneous pattern, such as in chronic obstructive pulmonary disease (COPD). Notably, PRM has been tested in COPD phenotyping in order to provide specific characterization of the predominant obstructive abnormality, and, therefore, optimize therapeutic strategy. Moreover, this quantitative assessment has been tested in longitudinal follow-up of COPD with promising preliminary results, thus fostering its employment as accurate complementary test to pulmonary function tests.

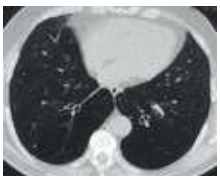

*Figure 1: Inspiratory CT shows low attenuation areas resembling panlobular emphysema of the lower lobes.*

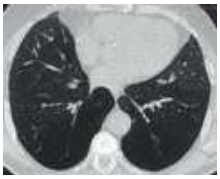

*Figure 2: Expiratory CT shows low areas attenuation with mild and ill-defined increase of density contrast, as compared to inspiratory CT.*

*Figure 3: PRM characterization of lung parenchyma shows normal tissue (green), air trapping (yellow), and emphysema (red). Air trapping is quantified as the predominant obstructive abnormality, despite the equivocal pattern at visual assessment.*

### Take Home Points

Parametric response map (PRM) is a quantitative method to assess tissue change by voxel-wise co-registration of volumetric imaging. PRM of combined inspiratory (Figure 1) and expiratory (Figure 2) CT of the lung allows differentiation between emphysema and air trapping (Figure 3). Chronic obstructive pulmonary disease can be characterized by PRM with objective apportioning of emphysema and air trapping, therefore fostering optimization of therapeutic strategy according to specific phenotype.

## Interval lung cancers: Definition and characteristics

*J.M. Goo; Seoul/KR*

### Body

Interval cancers are defined as cancers not detected by screening but diagnosed during the screening interval. These interval lung cancers include cancers diagnosed after a negative or indeterminate screening result (defined as no recommendation for referral) or after a positive screen in which diagnostic work-up did not lead to the diagnosis of cancer. Some researchers categorize interval cancers into "probably present" and "true interval cancer" by re-reviewing images. Diagnosis of interval cancer can be interpreted as a false negative result. Fast growing tumors, protocol inadequacies, protocol violations and missed cancers on CT can result in these cancers. Missed cancers can be caused by detection and interpretation errors. In detection errors the lesion is not mentioned in the report but can be seen in retrospect on the last CT, while in interpretation errors the lesion was noted but considered a benign lesion. Detection errors attribute to intrabronchial location,

adjoining bullous structure, lymphadenopathy, pleural effusion, extensive fibrotic change, pleural attachment, or human error. Compared with screen-detected cancers, interval cancers were reported to be at more advanced stages, more often small-cell carcinomas, and less often adenocarcinomas. Participants with an interval cancer are more likely to be current smokers that are participants with no cancer.

### Take Home Points

Interval cancers are defined as cancers not detected by screening but diagnosed during the screening interval. Interval cancers are diagnosed at more advanced stages, are more frequently nonadenocarcinoma, and are strongly associated with smoking. Endobronchial location of cancer and cancer presented as bulla wall thickening are frequent causes of detection errors for lung cancer.

## Nodule management: How to reduce false-positives?

*A. Devaraj; London/UK*

### Body

Although false positives are an inevitable component of lung cancer screening with CT, there is no widely accepted definition of what constitutes a false positive in lung cancer screening. Indeed the definition has varied substantially between lung cancer screening trials.
Since one of the major harms of false positives is that it can lead to additional unnecessary investigations and patient anxiety, one definition is that it represents any screening result that leads to patient recall prior to the next scheduled screening round.
Interventions to reduce the false positive rate are therefore important for successful screening implementation. It needs to be borne in mind that any changes to nodule management algorithms aimed at reducing false positives need to be applied without leading to an increase in missed lung cancers or lung cancers with stage progression.
Policies that may help achieve a consistent reduction in false positive rates include: i) selecting the optimal nodule size threshold for patient recall and/or pulmonologist referral; ii) use of lung nodule classification systems such as Lung-Rads; iii) use of volumetry applications and the calculated volume doubling time; and iv) improved interpretation of benign/indolent morphological features such as those belonging to so-called peri-fissural nodules or indolent non-invasive sub-solid nodules. This presentation will review the reliability of these various methods.

### Take Home Points

False positives are common in lung cancer screening with CT, and need to be minimized without increasing missed lung cancers.
Using nodule classification systems and nodule volumetry as well as optimizing nodule size thresholds in nodule management algorithms are methods that may reduce the false positive rate.

## Subsegmental PE: Diagnosis and management

*C. Schaefer-Prokop; Amersfoort/NL*

### Body

Attention to subsegmental PE (SSPE) has increased with the ability of CT pulmonary angiography (CTPA) to show such small emboli. The advent of multi-detector computed tomographic pulmonary angiography (CTPA) allows increased visualization of the peripheral pulmonary arteries. More cases of peripheral PEs, such as isolated subsegmental PE (SSPE) and incidental PE, have thereby been identified.
The prevalence of SSPE in patients with suspected PE varies between 0.4% and 18% according to the literature. It is likely that this variability is caused by patient characteristics, reading methodology but last not least by scanner technology used. A systematic review mentions a prevalence of SSPE of 4.7% in a group examined with a single slice scanner, and of 9.4% in a patient group examined with a multi-slice CT scanner.
In the PIOPED II trial the positive predictive value (PPV) of CTPA when compared to a composite reference was 98% for central but only 25% for SSPE pointing towards the lower diagnostic accuracy and reader confidence in diagnosing SSPE.

Clinical relevance and management of patients with symptomatic SSPE is still controversial. A Cochrane meta-analysis of 2014 summarized that there is no randomized controlled trial evidence for the effectiveness and safety of anticoagulation therapy versus no intervention in patients with isolated subsegmental pulmonary embolism (SSPE) or incidental SSPE. More and more publications occur describing outcome of untreated patients with SSPE that have no associated DVT. Recent recommendations from the European Society of Cardiology suggest an individualized approach for the management of patients with newly diagnosed SSPE based on the risk/benefit ratio of anticoagulation and the presence of lower limb DVT. Results of a still ongoing prospective trial (NCT 01455818) are expected to provide more evidence in that respect.

### Take Home Points

- To learn about prevalence, diagnostic sensitivity and accuracy of subsegmental emboli in various imaging techniques
- To learn about the literature evidence of the clinical meaning of subsegmental pulmonary emboli
- To get informed about the most recent developments about the clinical and therapeutic managment of subsegmental pulmonary emboli

## CT venography: When and how?

*B. Ghaye; Brussels/BE*

### Body

Since its introduction in 1998, the addition of CT venography to CT pulmonary angiography for the diagnosis of venous thromboembolism (VTE) has been a matter of debate. Many authors have pointed out that this combined CT technique substantially increases the radiation dose and potentially the overall cost of the examination. Furthermore, unlike when using single-detector row CT (SDCT), some authors have reported that venous ultrasound (US) investigation does not increase the detection of VTE nor decrease the 3-month recurrence rate when using multidetector row CT (MDCT) for CT pulmonary angiography. However CT studies have shown a different result: while the incremental value (ratio between the number of patients with DVT but without PE and the number of patients with VTE) was a mean of 23% (11-36% across studies) in studies using SDCT pulmonary angiography, this value is still substantial with a mean of 14% (0-33%) in 25 studies using 4- to 64-MDCT pulmonary angiography. A positive CT venography may also reinforce the diagnosis of VTE in a patient with isolated subsegmental PE or offset about one third of indeterminate CT pulmonary angiographies (reported in up to 13% of examinations).
The investigation of lower limb veins may also be of interest in patients with confirmed PE as patients with both PE and DVT have been shown to present with a greater risk of recurrence and death compared to those with PE alone. CT venography has been shown to be as accurate as venous US for the diagnosis of femoro-popliteal DVT. CT venography has nevertheless many advantages over US: it is less operator dependent, not limited by leg cast or painful compression, dressing, oedema, open wounds, severe burns or trophic changes of lower limbs or obesity. Patient comfort is increased, as no further mobilisation is required. CT venography provides adequate visualisation of veins or anatomic variants that are difficult to image with other techniques, such as iliac veins and IVC, which is advantageous to guide further interventions, such as catheter placement for thrombolysis or IVC filter introduction. CT venography also demonstrates unsuspected DVT in the opposite limb, adjacent disease or other anomalies compressing the venous system, and in some cases a malignancy as the underlying cause for VTE.
Many issues have to be further investigated: how to select the patients that may have the greatest benefit of CT venography? For this purpose, some authors proposed to use signs and symptoms or history of DVT, to determine high-risk groups or to use clinical scores. According to PIOPED 2, CT venography is most frequently positive in patients with symptoms and signs or with history of DVT. Other categories of patients may benefit of CT venography: ICU patients, patients with concomitant severe disease or trauma, patients at high-risk of indeterminate CT pulmonary angiography or in whom the diagnosis of VTE should be definitely confirmed or eliminated. Another major issue of scanning the lower limb veins is the radiation dose. All technical refinements decreasing the dose of CT venography should be systematically applied. The best technique for the acquisition, sequential vs helical, remains yet debated among authors. Also related to radiation dose is the extent of the acquisition range that remains a matter of debate, particularly at the level of the calf and the

pelvis. Excluding the pelvis from the scanning range may decrease the dose of CT venography by a factor up to 9, possibly without decreased diagnostic yield. Lastly, one of the main issues of CT venography is currently the dose of iodine that is required to obtain diagnostic-quality examinations. Most of the clinical studies still report a minimal volume of 100 ml of CM for the acquisition of CT venography, particularly in Caucasian patient. However, nowadays with 64-MDCT or other ultrafast CT, a volume of 20 to 50 ml of iodinated CM is sufficient to obtain high-quality CT pulmonary angiography. Future studies should concentrate on the combination of all methods allowing to achieve a better venous enhancement, including a low tube voltage, the use of monochromatic spectral images, an iso-osmolar contrast medium, vascular enhancement software or elastic stockings.

### Take Home Points

1. The combination of CT pulmonary angiography and CT venography allows for a one-stop shop examination of VTE
2. The incremental value of CT venography remains substantial (14%) when using MDCT pulmonary angiography
3. Further research is needed to limit the radiation dose and the amount of iodine required for the examination

## PE during pregnancy: How to optimise CT angiography?

*A. Leung; Stanford/US*

### Body

Pulmonary embolism (PE) is the leading cause of pregnancy-related mortality in the developed world. This presentation will review the diagnostic algorithm for suspected PE in pregnancy recommended by the American Thoracic Society/Society of Thoracic Radiology guidelines. In pregnant women in whom CT pulmonary angiography (CTPA) is indicated, optimization of technical parameters and contrast administration protocol is critical to achieve high quality, diagnostic studies.

### Take Home Points

- Evidence-based recommendations for diagnostic work-up of suspected PE in pregnancy are available
- Performance of CTPA in this population requires optimization of acquisition protocol to achieve high quality, diagnostic studies

## Incidental PE discovered during cancer follow-up CT

*A. Parkar; Bergen/NO*

### Body

Venous thromboembolism (VTE) is a common cardiovascular event with incidence of 100-200 per 100 000 inhabitants annually.
In oncology patients, VTE is more frequent as underlying cancer is an important and well known predisposing factor.
The reported prevalence rates of VTE are between 2-12% in oncology patients. Underlying cancer increases the risk of venous thromboembolism 4 times, and chemotherapy increases the risk 6.5times compared to general population.
The frequency of VTE is related to cancer types. It is more common in patients with malignant disease in the hematologic system, lungs, pancreas, stomach, ovaries, uterus, bladder and brain. Most reported VTE incidence or prevalence rates combine both deep venous thrombosis in extremities as well as pulmonary embolism (PE), and one suspects that the rates are higher as some are always clinically unsuspected and thus not registered.
The prevalence of PE in lung cancer patients is high as 3-18%. Retrospective studies of routine CT examinations have found that clinically unsuspected PE in cancer patients (as a whole group) has prevalence rates of around 2-3%. The rate of clinically unsuspected pulmonary embolisms in lung cancer patients has

been reported between 40-80%. The highest rate was actually seen in an out-patient population of lung cancer patients.
Several studies have shown that adenocarcinoma is more likely to cause PE, and also more likely to cause unsuspected PE, compared to other lung cancer types.
Incidentally discovered PE in lung cancer patients have a similar clinical course, risk of complications and mortality as patients with symptomatic pulmonary embolism. Thus recognising PEin cancer patients is crucial in order to initiate treatment, especially if patients are receiving chemotherapy.

### Take Home Points

1. Pulmonary embolism is common in oncology patients.
2. Patients with hematologic cancer and lung cancer are more prone to develop venous thromboembolism.
3. Patients who receive chemotheraphy have the highest risk of developing pulmonary embolism.
4. In lung cancer, adenocarcinoma is more often associated with asymptomatic pulmonary embolism.
5. Unsuspected pulmonary embolism has similar risk of recurrent disease and mortality as patients with symptomatic pulmonary embolism.

## Guidelines for nodule management: Theory and practice

*A. Bankier; Boston/US*

### Body

This presentation will present theory and practice of common guidelines designed to manage pulmonary nodules seen on CT. The presentations will explain the historical background and motivations for the guidelines. It will then show what potential and limitations the guidelines have. It will further discuss evidence about the current use of these guidelines in clinical practice and reserach. Finally, it will give a perspective on potential future guideline updates.

### Take Home Points

n/a

## Fleischner Society guidelines for solid and subsolid nodules

*H. MacMahon; Chicago/US*

### Body

The first Fleischner Guidelines for management of solid lung nodules were published in 2005, and have become widely accepted for determining the appropriate size threshold and follow up intervals for indeterminate small nodules. Due to a lack of data at the time, these recommendations did not specifically address the management of non-solid nodules, which were the subject of a second whitepaper that was published by the society in 2013. The purpose of these guidelineswas to provide evidence based recommendations to inform the clinical management of incidentally detected small lung nodules encountered on CTscans performed for purposes other than screening or cancer surveillance,with the intention of reducing the number of unnecessary follow up scans performed for benign nodules, while maintaining reasonably high sensitivity for cancer detection. A common source of confusion has been the differences between the FleischnerGuidelines and screening guidelines such as those issued by the American Collegeof Radiology (ACR). However, there is a critical difference between lung cancer screening and detection of incidental nodules: whereas a negative screening scan results in a follow upscan in 12 months, patients with incidental cancerous nodules who are not recalled for follow-up may not receive a diagnosis until they develop symptoms. Therefore, different guidelines for screening and for incidental nodules are appropriate. In addition, risk profiles and radiation risk may be substantially different in patients with incidentally encountered nodules, compared to patients in a screening program, who are selected based onrelatively advanced age and smoking history.Since the Fleischner Guidelines were written, additional information regarding cancer risk in small nodules has become available, mainly from lung cancerscreening programs in the USA, Canada and the Netherlands. Further studies of the relationship between CT and histopathological findings have also been performed, that serveto inform management strategies for non-solid nodules. Another important

development hasbeen the recommendation for adoption of low dose CT screening in high risk patients by multiple professional medical societies in the USA. Analysis of data from these programs hasprovided additional data that allows refinement of risk prediction, based on nodule size,morphology, location and underlying risk factors. Therefore, the current Fleischner NoduleGuidelines are under review by the society, with a view to incorporating these newer data,while recognizing and supporting the trend towards LDCT screening for asymptomatic highrisk patients. This presentation will discuss the relevant issues and data that will inform theupcoming revisions, pending consensus by the society and publication in the near future.

### References

MacMahon H, Austin JH, Gamsu G, Herold CJ, Jett JR, Naidich DP, Patz EF Jr, Swensen SJ, Fleischner Society: Guidelines for Management of Small Pulmonary Nodules Detected on CT Scans: A Statement from the Fleischner Society. *Radiology* 237: 395-400, 2005 PMID: 16244247
David P Naidich; Alexander A Bankier; Heber MacMahon; Cornelia M Schaefer-Prokop; Massimo Pistolesi; Jin Mo Goo; Paolo Macchiarini; James D Crapo; Christian J Herold; John H Austin; et al. Recommendations for the management of subsolid pulmonary nodules detected at CT: a statement from the Fleischner Society. *Radiology* 266, 304 (2013)

### Take Home Points

1. The Fleischner Guidelines for management of solid and subsolid lung nodules were published in 2005 and 2013, and have become widely accepted for determining the appropriate size threshold and follow up intervals for indeterminate small nodules.
2. New information has become available in recent years regarding the rsik of invasive cancer developing in lung nodules, and based on these data the Fleischner Society is currently working on a revision of the existing guidelines.
3. This presentation will discuss the relevant issues and data that will inform the upcoming revisions, pending consensus by the society and publication in the near future.

## Fibrosing lung diseases 2015

*N. Sverzellati; Parma/IT*

### Body

Several diseases variably associate with fibrosing interstitial lung disease (FILD). Among these, only a few are commonly encountered in routine clinical practice. High-resolution computed tomography (HRCT) has a central role in the investigation of patients with suspected FILD. In this context, a systematic approach to HRCT would be ideal. It should first entail evaluation of image quality, accurate description of specific disease features using standard terminology, and assessment of distribution of disease in both axial and cranio-caudal planes. The most important next step is to determine whether HRCT features permit a high-confidence diagnosis of usual interstitial pneumonia (UIP) (Fig. 1). In cases that do not meet strict criteria for UIP, the presence of traction bronchiectasis, architectural distortion or volume loss usually permit distinction of FILD from non-FILD. When findings are suggestive of a possible UIP pattern, differential diagnosis is less specific. In this setting the clinical problem most frequently encountered is distinguishing UIP from nonspecific interstitial pneumonia (NSIP) (Fig. 2). Additionally, identification of ancillary features such as cysts, perilymphatic nodules, centrilobular nodules, mosaic attenuation, pleural thickening or effusions, dilated esophagus, pleural plaques, sparing of the lung bases, or air trapping may increase suspicion of specific FILDs along with underlying association (e.g. collagen vascular disease, hypersensitivity pneumonitis, etc.) (Fig. 3).

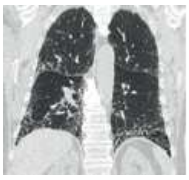

*Fig. 1. Coronal reformatted CT image shows subpleural basal honeycombing with traction bronchiectasis, reticular and ground-glass opacities. When idiopathic, this CT pattern is sufficient for the diagnosis of IPF.*

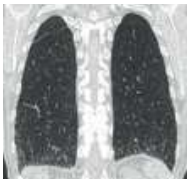

*Fig. 2. Coronal reformatted CT image shows basal predominant, peripheral predominant reticular abnormality with no honeycombing; although this patient is highly likely to have UIP, surgical lung biopsy is needed to confirm the diagnosis*

### Take Home Points

1. Radiologists should first distinguish fibrosing from non-fibrosing entities when reviewing HRCT of patients with suspected interstitial lung disease.
2. Three key observations indicate the presence of fibrosis: honeycombing, traction bronchiectasis, and signs of lung's volume loss.
3. The main CT differential of fibrosing lung disease is between the definite/possible UIP pattern and other fibrotic patterns such as NSIP and chronic hypersensitivity pneumonitis.

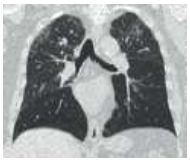

*Fig. 3. Coronal reformatted CT image shows ground glass and reticular opacities predominating in the upper lobes, an almost invariable finding in hypersensitivity pneumonitis.*

## Current knowledge on tumour induction by computed tomography

*A.R. Larici; Rome/IT*

### Body

It is well known that computed tomography (CT) examinations make nowadays the biggest contribution to the collective dose (from 46 % up to 80 %) of population exposed to X-ray for medical purposes. Ionising radiation may induce genetic mutations and even tumours and, therefore, benefit/detriment relationship should be always taken into account to justify its use. Current knowledge on the probability that CT examinations can induce tumour is under discussion among the scientific community. Although the probability that ionising radiation may induce a tumour is dose-dependent, other factors may affect the dose-effect curve, such as age, gender, modality and time of dose delivering, irradiated organ's type and environmental factors. Effective doses given in a single medical imaging exposure are universally within the low-dose range (<100 mSv). Therefore, risk estimation based on effective dose is clearly obsolete. Methods currently used to calculate the lifetime risk of cancer are based on risk coefficients risk, which depend on the dose rate, gender and age of the exposed person, and on epidemiological data derived from large studies assessing the ratio of tumour incidence between population exposed and unexposed to ionising radiation. These methods support the linear-no-threshold dose – response model at low radiation doses, even though uncertainties do persist. The best available risk estimates suggest that pediatric CT will result in significantly increased lifetime radiation risk over adult CT, and therefore paediatric CT protocols should always be standardised and acquired with low-dose algorithms. Nevertheless, if we considered that adult represent the largest proportion of patients receiving CT examinations, the probability of inducing a tumour by CT is even smaller. In addition, it should be always emphasised the great benefits that a examination may provide to an individual patient in personalised medicine, if properly justified. The "as low as reasonably achievable" (ALARA) principle must be considered when performing a CT examination and radiologists should be consciuous about dosimetry when approving a CT examination.

### Take Home Points

1. Estimates of induced cancers have recognized uncertainties that should be highlighted
2. Predictions of radiation-induced cancer should be discussed alongside benefits of CT imaging
3. The ALARA principle must be always considered by radiologists when performing a CT examination

## Indolent lung cancer: A new entity?

*J.M. Goo; Seoul/KR*

### Body

Indolent lung cancer shows slow growth causing no clinical symptoms and is closely related with overdiagnosis which is defined as detection of a cancer that would not otherwise have become clinically apparent. Overdiagnosis can cause potential harm to subjects who undergo screening by inducing additional cost, anxiety, and morbidity associated with cancer treatment. More identification of indolent cancers at screening has been reported since the screening trials using chest radiography. Based on these results that higher detection of early cancer did not lead to a decrease in advanced disease and frequency of interval lung cancers were same between the screening group and the control group, early lung cancer identified by screening is suggested to be not precursor of advanced disease. Recent low-dose CT lung cancer screening trials revealed that slow-growing or indolent cancer comprised approximately 25 percent of incident cases. Probability of overdiagnosis defined as excess number of lung cancers in the low-dose CT arm compared with the chest radiography arm was reported to be up to 18.5% in NLST cases. Although subsolid nodules have high likelihood of malignancy, these nodules are often indolent with long volume doubling time. Therefore, close follow-up with CT may be a safe option to monitor changes in subsolid nodules. As the ultimate goal of screening program is preferentially detect consequential cancer while avoiding detection of inconsequential disease, it is necessary to create observational registries for low malignant potential lesions for the risk of development of invasive cancers, the period of development, and the prognosis of those tumors.

### Take Home Points

Overdiagnosis, or identification of indolent cancer, is common and an intrinsic features of screening. Overdiagnosis is common in breast, lung, prostate, and thyroid cancer. Subsolid nodules are typical examples of indolent cancers and can be managed conservatively. Better characterizing the biology of lung cancer can result in better screening programs.

## Non surgical and surgical approaches for NSCLC

*F. Gleeson; Oxford/UK*

### Body

There are now multiple options for the non-surgical approach to NSCLC. This presentation will present the evidence for each of these approaches, and suggest how these might also be applied to metastatic malignancy.
The presentation will also discuss the morbidity and mortality of each method, and potential future advances. It will also discuss imaging techniques to assess treatment success.

### Take Home Points

- Both steoretactic beam radiotherapy (SABR) and percutaneous ablation have advantages and disadvantages
- Patient selection is important when determining which technique should be used
- Rigorous procedural quality control is critically important for technique success
- Imaging follow-up by protocol enables assessment of treatment success and the potential for identifying treatment failure and possible retreatment

## Imaging follow-up modalities after surgery for NSCLC

*Y. Ohno; Kobe/JP*

### Body

Patients with lung cancer are burdened with symptoms of recurrence as well as asymptomatic recurrence. Most guidelines suggest that follow-up should be done to manage complications related to the curative therapy itself. Guidelines also recommend surveillance to detect symptomatic or asymptomatic recurrence of the primary lung cancer and to detect a new primary lung cancer early enough to allow potentially curative retreatment.

Various surveillance strategies have been proposed, and a variety of imaging protocol from chest radiograph to whole-body CT and/ or integrated PET/CT with brain MRI has been proposed. On the other hand, detection of recurrent disease using standard methods such as chest radiograph and/ or CT was made difficult by the often extensive anatomic abnormalities that exist after definitive treatment for a few decades. For this reason, PET or PET/CT has been found more useful than standard methods for diagnosis of tumor recurrence and may well lead to major changes in management of patients with suspected recurrence. Recently, whole-body MRI and MR/PET are recently proposed as new whole-body imaging tools for not only tumor staging, but also surveillance of recurrence in oncologic patients.
In this lecture, I will present 1) current guidelines for follow-up examination in post-operative non-small cell lung cancer patients, 2) utility of PET or PET/CT for surveillance of recurrence as compared with whole-body CT, and 3) potential of whole-body MR imaging as well as PET/MR in this setting.

### Take Home Points

1. Understand he current guidelines for follow-up examination in post-operative non-small cell lung cancer patients
2. Determination the utility of PET or PET/CT for surveillance of recurrence as compared with whole-body CT
3. Demonstration of the potential of whole-body MR imaging as well as PET/MR for postoperative NSCLC patients' management

## Lung nodule diagnosis: Common pitfalls

*E. Coche; Brussels/BE*

### Body

This presentation will focus on the most common pitfalls encountered in the diagnosis of lung nodules using chest radiography, Computed tomography and PET-CT. The pitfalls can be categorized as errors of detection, characterization, including equivocal or atypical presentations. Follow-up errors will also be presented.
Tips and tricks will be provided to the audience in order to avoid misinterpretation that can alter patient management.

### Take Home Points

1. Viewing lung nodules in various projections using multiplanar reconstructions is useful to further characterize lung nodules and to differenciate them from linear atelectasis or elongated areas of scarring.
2. The use of thin-section and reconstruction intervals with dedicated filters is mandatory to decrease partial volume effect, increase spatial resolution and avoid artefacts.
3. The use of maximal intensity projections is mandatory to increase the detection of lung nodules.
4. The use of automated or semi-automated computerized 3D measurements is recommended to better assess the interval growth of lung nodules.

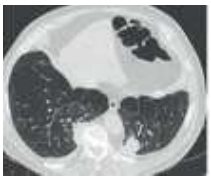

*Chest CT revealed a lung nodule at the left lower lobe (straight arrow). This lesion is in subpleural location and abuts an area of pleural thickening containing calcifications. This nodule corresponds to a round atelectasis due to asbestos exposure.*

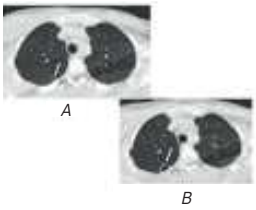


*Young patient adressed for osteosarcoma. Chest CT was performed on may 2011 (A) and November 2011 (B). An isolated cystic airspace (straight arrow) mimicking a postinflamatory lesion or focal emphysema was due to cystic metastasis.*

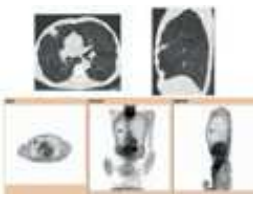

*57-year-old man, heavy smoker was adressed for lung cancer screening. A chest CT was performed and revealed a elongated nodule in the right middle lobe. PET-CT was positive. Pathology revealed inflammatory cells in relationship with round pneumonia.*

## Pulmonary embolism diagnosis

*N. Screaton; Cambridge/UK*

### Body

Acute pulmonary embolism is common and carries significant mortality and morbidity. Rapid diagnosis and initiation of treatment improves outcomes. CT pulmonary angiography is the current reference standard in pulmonary embolism diagnosis enabling diagnosis both of pulmonary embolism or an alternative cause for the patient's symptoms as well as risk stratification. However there has been rapid increase in use of the technique accompanied by reduction in diagnostic yield in recent years with significant contribution to population radiation burden. While rapid and accurate diagnosis and early discharge may be achieved by the widespread use of CTPA as pre-test likelihood of PE falls so too does the effectiveness of the study.
Pitfalls in pulmonary embolism diagnosis thus relate not only to suboptimal images (whether due to technique, co-morbidity, or patient factors), misdiagnosis (relating to mimics of disease), but also to overutilization of imaging or inappropriate diagnostic pathways, as well as over diagnosis of disease.

Over-utilisation of imaging: Acute PE often presents with non-specific clinical features however the combination of clinical score (Wells or Geneva) and D-Dimer permit PE to be safely excluded in 20-30% of patients without recourse to imaging when clinical probability is low and D-Dimer normal. Further refinement to interpretation of the D-Dimer result to account for the normal increase with age permit further selection of the patient population suitable for imaging, limiting radiation burden, potential nephrotoxicity, and optimizing resource utilization

Over-diagnosis of sub segmental PE: While historically the sensitivity of CTPA to sub-segmental emboli was questioned but advances in technology have lead to rapid improvements to the extent that diagnosis of isolated sub-segmental emboli will in specific circumstances not routinely require anticoagulation.

Technical optimization: Advances in technology have led to opportunities for marked radiation and contrast medium dose reduction but also to increased need to personalize imaging such that image noise is managed and contrast opacification is optimised. Despite advances in technology the frequency of non-diagnostic studies remains in the 5-10% range.

*Dose reduction and improved temporal resolution:*

Low kV technique permits marked reduction in radiation dose while preserving image quality. However in patients with high BMI >30kgm-2 low dose technique results in reduced image quality due to increased noise so should be avoided in this patient cohort. Similarly increasing pitch can lead to dose reduction, improved temporal resolution with reduced cardiac and respiratory motion, but limitations of photon flux may lead to reduced image quality in obese patients. Combining low kV and high pitch techniques can lead to marked reduction in radiation dose but image quality is adversely influenced by increase in BMI. The latter can be offset at least in part by the use of high output tube in modern scanners or the use of iterative reconstruction techniques. Further dose reduction techniques include tube current modulation, automated tube voltage selection, and limited Z-axis coverage and collimator usage to prevent over-scanning.

*Contrast timing issues:*

Rapid acquisition and the use of low dose technique have also led to reduction in the volume of contrast medium required. While these carry benefits they reduce the window for optimal contrast opacification of the pulmonary arteries. Opportunity for missing peak enhancement is increased requiring careful consideration of factors such as breathing technique, bolus triggering, and patient factors such as pregnancy. Similarly attention needs to be paid to potential beam hardening from contrast in the SVC, which can be overcome using saline chaser, split bolus or bolus shaping techniques.

Mimics of pulmonary embolism:

There are numerous factors that may mimic filling defects of acute pulmonary emboli. These range from artifacts such as respiratory or cardiac motion through misinterpretation of venous or bronchial structures to true pulmonary arterial abnormalities not due to acute emboli. The latter include chronic thromboemboli, in situ thrombosis, pulmonary artery sarcoma and large vessel vasculitis. With careful evaluation these diseases are generally readily differentiated on imaging and clinical grounds.

### Take Home Points

Common pitfalls in pulmonary embolism diagnosis include:

1. Non-diagnostic examinations which can be reduced by careful attention to imaging technique, co-morbidity, and patient factors
2. Misdiagnosis or overdiagnosis of pulmonary embolism due to artefact or mimics of disease
3. Overutilization of imaging or inappropriate diagnostic pathways

## Pleural plaque diagnosis

*C. Beigelman-Aubry; Lausanne/CH*

### Body

CT diagnosis of pleural plaque(s), usually performed in a context of a previous asbestos exposure, rests on strict technical and interpretation criteria. For the latter, a good knowledge of pleural and intercostal space anatomy is required to avoid potential pitfalls. Thin-section evaluation in full inspiration allows accurate assessment of real pleural plaques in most cases. Additional coronal or sagittal reformats may be helpful in cases of atypical or doubtful features on axial sections. When faced with common non-calcified focal pleural thickenings located at the posterior part of the lower lobes, an additional low-dose acquisition focused on the abnormal areas should be obtained in prone position. Resolution of these anomalies in prone position confirms their functional nature and excludes the diagnosis of pleural plaques. False positive or negative results may induce adverse psychological consequences and may delay the diagnosis of an actual pleural tumoral involvement. Furthermore, pleural plaques may be an independent risk factor for lung cancer death in asbestos-exposed workers. Typical pleural plaques are circumscribed and discrete areas of hyaline or calcified fibrosis, which are localized on the parietal pleura of the lateral chest wall, the diaphragm, or the mediastinum, and in most cases occur below the level of the aortic arch. They may or not be calcified, are single or multiple, of variable size and extent with sometimes an irregular or nodular appearance. Contrarily to the easily recognized extra-pleural fat, anatomical structures such as muscles or veins may induce false positive results. Pleural thickening associated with crow-feet images, parenchymal bands or rounded atelectasis should not be confused with pleural plaques. These features suggest a visceral pleural fibrosis that may be related to sequelae of any cause of pleural effusion. Pleural thickening in a context of previous infectious disease, especially tuberculosis (TB), should suggest the possibility of pleural sequelae and not be reported as pleural plaques, although some difficult cases may be encountered. In cases of previous TB, lung scarring with volume loss occurs in the upper lobes with nodules or linear densities located in the apices, especially in the subpleural area, while pleural thickening, calcified or not, usually predominates above the aortic arch. Silicosis may also give rise to pleural plaque-like anomalies. In this setting, the upper location of pleural thickening, the associated perilymphatic nodules as well as the exposure history are helpful for the final diagnosis. Sarcoidosis may also present with anomalies suggesting pleural plaques. Mediastinal lymph nodes and perilymphatic micronodules suggest the diagnosis. An atypical shape and/or location of a focal pleural anomaly should always evoke the possibility of a pleural metastasis, especially in context of thymoma, breast, pulmonary, renal or ovarian carcinoma, lymphoma or Kaposi sarcoma as well as an early mesothelioma. Although PET contribution may be limited by low spatial resolution or low F-18-FDG uptake of the primary tumor, significant activity can be observed in cases of pleural metastasis. Finally, drug-induced pleural changes should be kept in mind.

### Take Home Points

- Typical pleural plaques are localized on the parietal pleura of the lateral chest wall, the diaphragm, or the mediastinum, and in most cases occur below the level of the aortic arch
- Non-calcified focal pleural thickenings located at the posterior part of the lower lobes require an additional low-dose acquisition focused on the abnormal areas in prone position to precise their potential functional nature.
- Differential diagnoses including pleural metastases must be kept in mind.

## Common pitfalls in.... interstitial lung disease

*D. Lynch; Denver/US*

### Body

Pitfalls in diagnosis of interstitial lung disease can be grouped under the following headings:

Technical pitfalls

Lack of prone images. While prone imaging is not necessary in every case, it is often very helpful in distinguishing between dependent atelectasis and true disease, and in identification of subtle honeycombing

Lack of expiratory images. Expiratory images are critical in the diagnosis of hypersensivity pneumonitis, obliterative bronchiolitis, and other obstructive lung diseases.

Lack of contiguous images. Contiguous imaging is important because of the common occurrence of focal lung abnormalities (particularly lung cancer) in subjects with interstitial disease.

Lack of multiplanar reconstructions. In particular, coronal reconstructions are very helpful in identifying craniocaudal and axial disease distribution, and in distinguishing between linear atelectasis and ground glass abnormality.

Excessive edge enhancement. High resolution CT images should be reconstructed with an algorithm that favors high spatial resolution. However, excessive edge enhancement seen with some reconstruction algorithms makes diagnosis difficult because of noise.

Inadequate inspiration. High resolution images should always be acquired at maximal inspiration. Inadequate inspiration can simulate ground glass attenuation and distort lung anatomy.

Motion artifact. Motion artifact can almost always be avoided by careful communication between technologist and patient, and by repeating scans with motion.

Interpretive pitfalls

Honeycombing. Honeycombing is pivotal in diagnosis of UIP and idiopathic pulmonary fibrosis. The diagnosis may be made by finding clustered subpleural cysts. Although difficulties may arise in distinguishing honeycombing from subpleural emphysema and from traction bronchiectasis, it remains a very useful sign.

Crazy paving pattern. The term crazy paving is sometimes used to describe a reticular pattern superimposed on ground glass opacity, with resulting loss of diagnostic specificity. This term should be reserved for subjects with obvious sharply defined thickening of interlobular septa and intralobular linear structures, superimposed on ground glass abnormality, without evidence of fibrosis. In this context, the crazy paving pattern is almost always due to pulmonary alveolar proteinosis or occasionally lipoid pneumonia.

Mosaic attenuation. While classic descriptions suggest that expiratory images can be used to distinguish mosaic attenuation due to obstructive lung disease versus pulmonary vascular disease in subjects with mosaic attenuation, it must be recognized that vascular disease may sometimes be associated with air trapping.

Air trapping. Heterogeneity of lung attenuation on expiratory CT is not always due to air trapping. Conversely, diffuse homogenous air trapping is often missed.

Overdiagnosis

UIP. Overdiagnosis of UIP is the commonest form of misdiagnosis seen on outside referrals to our practice. The most common sources of misdiagnosis are hypersensitivity pneumonitis and drug toxicity. This form of misdiagnosis is likely to increase with the new availability of treatments for idiopathic pulmonary fibrosis.

NSIP. Radiologists now understand that honeycombing is uncommon in NSIP. However, this does not mean that every fibrosing interstitial pneumonia without honeycombing represents NSIP. Precise CT diagnosis of NSIP remains challenging.

Lymphangioleiomyomatosis. Cystic lung disease occurring in a young or middleaged woman commonly leads to the misdiagnosis of LAM. The radiologist should be aware of the imaging features that permit differentiation among the cystic lung diseases

Underdiagnosis

Hypersensitivity pneumonitis. Despite often typical imaging appearances, the diagnosis of HP is quite often missed.

Pulmonary drug toxicity. Pulmonary drug toxicity due to nitrofurantoin or amiodarone usually leads to an organizing pneumonia pattern. While it is difficult to make a confident diagnosis of drug toxicity on CT alone, a brief review of the medication list can be very helpful.

Radiologic-pathologic discordance
Although radiologic and pathologic diagnoses are often in agreement, biopsy is now rarely performed in those with typical imaging appearances of specific disorders, particularly UIP. When biopsy is performed in non-classic cases, radiologic-pathologic discordance is common.

### Take Home Points

Attention to technique is the most important factor in accurate diagnosis of interstitial lung disease.
Other important considerations are precision in recognition of diagnostic signs, and avoidance of overdiagnosis or underdiagnosis of specific conditions.
Radiologic pathologic discordance may be best handled by understanding the relative limitations of radiologic and pathologic diagnoses.

## Structured reporting

*Th. McLoud; Boston/US*

### Body

The objectives of this lecture are to allow the audience to understand the motivations for templated and structured reporting, to review the evidence in favor of structured reporting, to instruct the audience how to access tools to build consistent structured reports in their practice, and present possible applications of structured reporting in thoracic radiology particularly reporting of lung cancer screening chest CT.
A structured report is a pre-defined report organization used repeatedly. It may also include preferred common language to describe findings and diagnoses. Such an approach has certain advantages which limit inconsistency, confusion and ambiguity . Preferred terms and definitions are used consistently which facilitates teaching, research and and clinical practice for referring physicians. Structured reporting also reduces the chance that content will be missed by providing check lists. Vendor systems and voice recognition dictation create an environment that is template friendly and the RSNA is in the process of developing template libraries.
We all resist change but incentives to adopt structured reporting include group involvement in the creation of the reports and group financial incentives for adherence to structured reporting. Guidelines for management such as the Fleischner recommendations for follow-up of pulmonary nodules can be imported into structured reports. Lung-RADS is a structured reporting system which provides a standardized language similar to BI-RADS for reporting findings in lung cancer screening chest CT. Guidelines and recommendations for follow-up of pulmonary nodules can be easily incorporated into a structured reporting system.

### Take Home Points

Structured reporting is in your future.
Templates will soon be available.
Facilitates reporting for Lung-RADS, BiRADS

## Multidisciplinary conferences

*J. Verschakelen, W. de Wever, J. Coolen; Leuven/BE*

### Body

A multidisciplinary conference (MDC) can be defined as a conference where a group of people of different health-care disciplines ( the multidisciplinary team (MDT)) meets together at a given time (in one place or by video- or tele-conferencing) to discuss a given patient in order to contribute independently to the diagnostic and treatment decisions about this patient (adapted from a definition by the UK Department of Health). While team composition very much depends on the disease of the patient and on the diagnostic and therapeutic decisions that need to be made, it is generally accepted that the radiologist is an important member of such a MDT.
Nowadays MDC's form part of the daily work in most hospitals caring for cancer patients and many potential advantages of this multidisciplinary work have been recognized and published in the field of lung cancer. Although introduced later, a multidisciplinary approach is also central to the diagnosis and even the treatment planning of patients with diffuse lung disease and compels the installation of a multidisciplinary

team especially when dealing with patients suspected of having an idiopathic interstitial lung disease . In this presentation the advantages but also the potential pitfalls of such a multidisciplinary conference together with the requirements for effective MDT working will be discussed.

### Take Home Points

- Multidisciplinary conferences improve patient care and are central to the management of patients with lung cancer and diffuse and interstitial lung disease.
- The radiologist is an important member of the multidisciplinary team.
- Multidisciplinary conferences need to be well prepared and well organized in order to be effective.

## Publishing in imaging journals

*N. Karabulut; Denizli/TR*

### Body

Learning Objectives

- To understand the basic principles of manuscript writing
- To be familiar with the requirements of manuscript submission

Getting a research paper published can be a challenging task. However, a well-designed and elegantly prepared manuscript conveying novel and important information with a high level of integrity and honesty is likely to be published when submitted to an appropriate journal. Herein I will summarize some writing and submission tips for increasing the likelihood of a manuscript to be published.

Conduct a good study: Three pillars of a good study are novelty, importance and accuracy. The topic must be novel (add new information, provide new concepts, describe new techniques, define new diagnostic or therapeutic approaches, or resolve existing controversies), important (change current practice, help understand mechanisms, generate a new hypothesis and stimulate further research) and accurate (appropriate and reproducible methodology, proper analysis and consistent conclusions).

Present your study well: The "presentation" of a manuscript can be almost as important as the scientific quality of the study. The "presentation" includes clear and simple writing style, neatness (correct syntax, lack of misspelled words and typographical errors), and quality of images, tables, and references. Follow the IMRaD (Introduction, Methods, Results, and Discussion) framework in writing.

- Introduction (3 paragraphs): First two paragraphs should briefly define the problem and current knowledge and provide a rationale for the study. The third paragraph should state the research question. Avoid giving an encyclopedic review of all related literature.
- Methods (3-5 paragraphs): The employed methods should be described in detail and step by step, so that readers can reproduce exactly what you did. This section can be better organized under subheadings and provide detailed information about subject selection, ethical approval, imaging procedures, definitions and criteria, image interpretation, and statistical analysis. Pay attention to the STARD Checklist (www.stard-statement.org) which is an excellent guide for any clinical manuscript.
- Ethical approval: Studies involving human or animal participants must be approved by the appropriate ethics committee. Prospective human studies require both approval and informed consent by participants. Retrospective studies require approval with waiver of informed consent.
- Results (3-4 paragraphs): Your results are the most important part of the manuscript, and the results section should parallel that of the methods section. If subheadings are used in the methods section, then the corresponding subheadings can be provided in the same order in the results section. Present your findings clearly by avoiding long and confusing sentences. You can shorten the results by presenting your data in tables and figures.
- Discussion (5-6 paragraphs): Start this section by summarizing the main finding of your study. Then, describe the novelty of your findings and state whether your results parallel or contradicts previous research. Avoid repeating the introduction, nor present any new data that were not shown in the results section. Describe your limitations before the conclusion paragraph. Finally, write a strong conclusion by summarizing your primary findings, and the potential significance and/or clinical implications of your findings. The last sentence should describe the logical next step (e.g. future studies), if needed.

- Abstract: The abstract should be written after all the basic components of the paper have been completed. Since it is a distillation of the study, it should be structured along IMRaD subheadings. The purpose of the study should be encapsulated in one or two sentences. The methods paragraph should include only an outline of the procedures and variables. The results should report only the principal findings of the study with salient statistics. The conclusion should be limited to one or two sentences and should directly reflect the words of the purpose.
- Title: The title sells the paper. Think what "take home message" you'd like to deliver and write your title. A good title (typically 10–12 words long) should use descriptive terms and phrases that accurately highlight the core content of the paper.

Before submitting your manuscript:
- Revise the first draft; delete redundant and unnecessary parts, reorder or restructure things to be coherent. You may repeat this process 2-3 times.
- Pass the paper to your coauthors and get their comments to shape the next draft.
- Before you send the paper out, force yourself to read it carefully one last time, making sure that the numbers all add up, that there are no gross misspellings or grammatical errors, and that the references are in the order of their callouts in the text.
- Pay full attention to universally accepted standards of manuscript submission recommended by international authorities such as the International Committee of Medical Journal Editors (ICMJE) (www.icmje.org). These include scientific integrity, ethics, authorship, conflict of interest disclosure, and copyright transfer.

While submitting your manuscript:
- Journal selection: It is important to select the right journal to publish your study. Since most journals are very specific in their subject area, be sure that the topic of your study matches with the journal's aim and scope and types of articles it publishes (case report, original article, review, pictorial essay). Also consider the target readership, the visibility, turnaround time, and reputation (indexing level, impact factor, peer review, editorial board, quality of accepted articles and authors) of the journal. Be cautious for predatory open access journals.
- Journal guidelines: Adhere to the "Guidelines and Information for Authors" of the journal you wish to submit. Authors need to make every effort to ensure that their manuscript is in full compliance with the journal's instructions in order to avoid unnecessary delays in the peer review process.
- Cover letter: Provide detailed information in the cover letter including a full statement regarding the originality of the manuscript. All previous publications or meeting presentations that might be regarded as redundant or duplicate publications must be expressed along with submission of prior similar works.
- Copyright transfer form: This form is a prerequisite during submission and addresses several items that all authors must certify when signing the form. These items define the scientific integrity, ethical aspects, conflict of interest disclosure and authorship issues. By signing the copyright agreement, the authors hand over the copyright of their work to the publisher of the journal. Therefore, republishing or reusing the copyrighted materials (text, tables and images) including author's own works requires documentation of permission from the publisher, and it should be presented with the cover letter. Authors must also understand that by signing the copyright transfer agreement, they accept to become a part of any potential misconduct investigation, and any disciplinary measures. Therefore, individuals should avoid putting their names in the copyright transfer form if they do not meet the authorship criteria.

**Take Home Points**
- Perform a good (novel, important and acuurate) study.
- Present your study well: Follow the IMRaD (Introduction, Methods, Results, and Discussion) framework in writing. Check out STARD nad ICMJE guidelines.
- Select an appropriate journal to publish. Be cautious for predatory open access journals.
- Adhere to the "Guidelines and Information for Authors" of the journal.
- Provide detailed information in the cover letter including a full statement regarding the originality of the manuscript.
- Read, understand and sign the copyright transfer form.

## How to avoid Bias in imaging studies

*D.J. Boone[1], S. Halligan[2], S. Mallett[3], S.A. Taylor[2], P.D. Altman[4]; [1]Colchester/UK, [2]London/UK, [3]Birmingham/UK, [4]Oxford/UK*

### Body

Bias is a form of systematic error that impacts upon the validity of radiological studies. Hence, avoidance of bias underpins the design and appraisal of research methodology. Furthermore, it is crucial that studies evaluating diagnostic test performance remain transferrable to daily practice. However, balancing avoidance of bias with generalisability is not straightforward.

For example, while it is generally accepted that clinical information that could influence subjective assessments should be concealed from trial observers, this conflicts fundamentally with clinical interpretation; such information is routinely integrated while forming a radiological opinion. Likewise, although pragmatic constraints often require interpretation of selected, pathology-enriched datasets this does not reflect daily clinical practice, particularly when considering screening environments. Study design is complicated further when evaluating novel imaging technologies against current accepted practice: Bias may result from an imperfect reference standard and the repeated reading of datasets by the same observers, could introduce recall bias.

Nevertheless, while numerous sources of potential bias have been described, their impact on results remains largely unquantified. Therefore, recognition of strategies employed to minimise bias and their potential impact on generalisablity is essential, not only for those involved in study design but, moreover, for all radiologists incorporating research into their evidence-based practice.

This session presents the results of a systematic review designed to identify and quantify a number of less well-known sources of bias including 'prevalence effect'; 'observer recall bias'; 'context bias' and the 'laboratory effect.' Data are presented, their potential impact discussed and suggestions are made for much-needed additional research into this field.

### Take Home Points

- Numerous sources of bias exist that influence the validity of radiological research.
- Avoidance of bias underpins the design and appraisal of research methodology.
- Methodology designed to minimise bias may adversely affect the generalisability of research or may introduce additional, less well-known sources of bias.
- The impact of several sources of bias remains unquantified.
- Recognition of strategies employed to minimise bias and their potential influence on generalisablity is essential for evidence-based practice.

## Tumours of the anterior mediastinum

*E.M. Marom; Ramat Gan/IL*

### Body

Mediastinal masses are relatively uncommon. Because there is such a wide variety of pathologic entities that can occur in the mediastinum, the average radiologist or clinician will encounter many of these specific lesions infrequently. Imaging is a critical part of establishing a presumptive diagnosis, which will guide whether and what type of confirmatory testing is needed. When classic features are present, a presumptive diagnosis can be made with a high degree of confidence based on imaging alone. However, the appearance of anterior mediastinal lesions is often nonspecific. In this lecture we shall review:

1. The recently accepted anatomic CT based mediastinal division into compartments
2. Imaging approach to the anterior mediastinal mass
3. Highly characteristic lesions by imaging, so that when their characteristic imaging features are seen, a diagnosis can be made by imaging alone:
   - Goiter-hyperdense and enhancing lesion with connection to thyroid
   - Benign teratoma- heterogeneous with fat, fluid, soft tissue and calcification
   - Thymic cyst-Well-circumscribed, round/oval/saccular, and homogeneous mass near the thymic bed
   - Pericardial cyst- Purely cystic lesion in cardiophrenic angle

4. Lesions with a suggestive diagnosis on imaging, for which the correct clinical context can establish the diagnosis. We will review the limited clinical data needed for establishing the correct diagnosis in this category such as age, gender, and presenting symptoms- information which is readily available on limited requisitions. The tumors covered will include: thymoma, Hodgkin's lymphoma, mediastinal large cell non-Hodgkin's lymphoma, lymphoblastic non-Hodgkin's lymphoma, nonseminomatous germ cell tumor, seminoma, thymic cancer, thymic hyperplasia.
5. Rare tumors such as: lipoma, thymolipoma and liposarcoma.
6. Confirmatory imaging or biopsy tests which are most beneficial in particular situations
7. We will discuss the radiologist's role in the implementation of the recently proposed ITMIG/IASLC thymic epithelial tumors staging system

With a structured approach to the anterior mediastinal mass, eliminating the masses diagnosed with confidence by imaging alone, limiting differential diagnoses for tumors with inconclusive imaging features, and by offering meaningful confirmatory imaging or biopsies, our role as radiologists will be meaningful, and will shorten the time from presentation to diagnosis in an efficient fashion.

### Take Home Points

When a characteristic imaging appearance is present, a difinite diagnosis can be made by imaging alone for: goiter, benign teratoma, thymic cyst and pericardial cyst.
In most other anterior mediastinal tumors, limited clinical information correlation can create a presumptive diagnosis

## Tumours of the posterior mediastinum

*M. Occhipinti; Rome/IT*

### Body

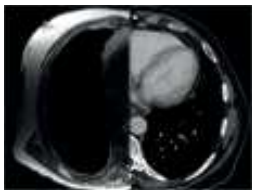

*Combining CT & MRI*

Tumors of the posterior mediastinum are mainly represented by neurogenic tumors. However, several pathological conditions can be located in the posterior mediastinum, making their differential diagnosis very challenging at times. These conditions arise from diverse anatomical structures, such as esophagus, lymph nodes, adipose tissue, nerves, aorta, azygos and hemiazygos veins.
Although chest radiograph may detect many of these pathological conditions, computed tomography (CT) and magnetic resonance (MR) are the imaging modalities of choice for a precise characterization of all the lesions. Each modality shows specific imaging features. Indeed, CT allows evaluating the presence of calcifications, erosion or scalloping of ribs or vertebrae, distant metastases, whereas MR allows evaluating the extension into the spinal canal, invasion of the nerve roots, presence of viable tumor or only residual fibrosis after treatment. Radiologists can use both CT and MR to narrow the spectrum of differential diagnosis, to offer an accurate staging of malignant disease, and to provide the surgeons with precise information for treatment planning. Finally, hybrid imaging with 18F-FDG-PET scanning can help to improve the accuracy of staging of distant disease and to evaluate response to treatment.
This talk emphasizes modality-related answers to morphological questions, needed for both diagnosis and follow-up of posterior mediastinal tumors.

### Take Home Points

Integration of CT and MR findings is fundamental to narrow the broad spectrum of differential diagnosis of posterior mediastinal lesions. Integration of CT, MRI and 18F-FDG-PET scan allows an accurate staging of malignant disease and provides the surgeons with essential clinical information for treatment planning and follow-up.

## Tumours of the middle mediastinum

*Ch. White; Baltimore/US*

### Body

#### Overview

The mediastinum is demarcated anteriorly and posteriorly by the sternum and spine, respectively, and laterally by the mediastinal pleurae. Using the lateral radiograph, it is customary to divide the mediastinum into anterior, middle, and posterior components. The various classification systems use different points of division. However, in general, the anterior mediastinum is anterior to the trachea and the posterior mediastinum is delimited by an imaginary line one cm behind the anterior spinal margin. The middle mediastinum lies between the two other segments. Because lesions tend to localize to specific areas, knowledge of the location of a mediastinal abnormality allows proper consideration of the diagnostic possibilities.

#### Anterior Mediastinal Lesions

The conventional approach to anterior mediastinal lesions is to consider the "four T's" (thymoma, teratoma, thyroid tumors, and "terrible" lymphoma) which is useful as a starting point.

#### Middle mediastinal lesions

Middle mediastinal lesions include foregut duplication cysts, esophageal lesions, lymphadenopathy, and vascular anomalies. The most important of the foregut duplication cysts is the bronchogenic cyst.

#### Posterior Mediastinal Masses

The majority of posterior mediastinal masses treated surgically are neural tumors. Lymphadenopathy may also occur as a mass in this location. Less common entities include lateral meningocele, pancreatic pseudocysts, extramedullary hematopoiesis, and neurenteric cysts.

### Take Home Points

1. To describe the various divisions of the mediastinum as visualized on the lateral radiograph.
2. To discuss the clinical and imaging findings of lesions of the anterior, middle, and posterior mediastinum, featuring cross-sectional imaging techniques with pathological correlation.

## How and when to perform CT biopsy for mediastinal lesions

*J. Klein; Burlington/US*

### Body

The use of computed tomographic guidance allows for safe and accurate percutaneous sampling of a spectrum of mediastinal and hilar lesions. This presentation will review the technical aspects of CT imaging to guide mediastinal biopsy, the situations where it has been shown to be effective for diagnosis, the approaches used for safe access to the lesion in question, and sampling techniques to be employed in specific situations including when to employ core tissue biopsy. The pertinent literature that has assessed the use of CT-guided percutaneous biopsy for pathological diagnosis of mediastinal and hilar lesions will be reviewed.

### Take Home Points

Computed tomography allows for safe access to most mediastinal and hilar lesions.
A definitive pathological diagnosis can be achieved in the vast majority of patients.
Core tissue biopsy, which can otherwise only be obtained surgically, can provide a diagnosis in cases where cytologic diagnosis may be difficult or impossible.
A variety of manuevers can be used to access mediastinal lesions by employing an extrapleural appraoch and thereby minimize the risk of biopsy-induced pneumothorax.

## Reporting cardiac findings on chest CT

*Ch. Loewe; Vienna/AT*

### Body

Due to the close functional and anatomical relationship between the heart and the lung, it can't be avoided to image the heart during chest CT examinations. Traditionally, only limited attention was paid to the white structure in the middle of the thorax representing the heart. However, with the currently used modern second and third generation CT scanners, the heart is visualized with an image quality that the heart can't be neglected anymore.
The question how detailed cardiac findings have to be reported on Chest CT scans becomes even more crucial due to the introduction of lung cancer screening by low dose Chest CT. The question what to report, how to describe – and even more difficult – how to proceed with the cardiac findings reported from screening chest CT is not answered yet, and no clear data do exist regarding this issue. It seems to be critical to generate "patients" based on incidentally reported cardiac findings during screening chest CT and to force them into cardiac diagnostic pathways by overdiagnosis. On the other hand side, given the well known close relationship between cardiovascular risk factors and risk factors for bronchial carcinoma, it seems to be of high interest to describe cardiac findings predictive for increased cardiovascular risk during screening examination.
Additionally to the not yet solved problem about how to deal with cardiac findings during bronchial carcinoma screening, reporting of cardiac findings are of special importance even in patients suffering from different lung diseases. It is well known that cardiac complications are the most frequent post-operative complications after lung surgery, and some of these possible complications can be predicted by cardiac findings on chest CT.
In this presentation possibilities and limitations of describing cardiac pathologies on chest CT will be discussed. Possible algorithms how to approach the heart on normal, not-triggered chest CT will be proposed to remain as accurate as possible, but to avoid false positives in the same attempt. The most recent literature and existing guidelines will be introduced to provide practical recommendations for the daily clinical work.

### Take Home Points

The close relationship between risk factors for bronchial carcinoma and cardiovascular diseases necessitates comprehensive approach to chest CT Guidelines and recommendations are needed how to proceed with incidental cardiac findings on low dose screening CT of the chest Cardiac diseases can influence the outcome after lung surgery whereas they need to be reported on chest CT

## What to say about the coronary arteries?

*S. Padley; London/UK*

### Body

Historically the radiologist has not reported coronary artery calcification on non gated CT of the thorax, mainly because of motion unsharpness, but also because of the uncertainty of the significance of this finding. This talk will review the evidence that now exists regarding coronary calcification on ungated CT, and will give the listener a simple guide for reporting this frequent finding based on the current literature.

### Take Home Points

- Coronary calcium is a frequent finding on non gated thoracic CT
- There is now a clearer understanding of the importance of this finding
- Relevant comment on this finding should be routine in thoracic CT interpretation

## Fatty images of the heart

*M. Francone; Rome/IT*

### Body

Fat tissue is a normal component of the heart variably stored in the subepicardium depending on age and obesity/metabolic condition, or arising de novo from pluripotential interstitial cells or cardiac myocytes.
The main clinical challenge remains differentiation between normal and pathological representation of adipose tissue within the human heart since fatty infiltration promotes arrhythmogenicity and/or causes sudden death infiltrating conduction system and producing atrophy and degeneration of adjacent myocardial cells due to loss of intercellular communications.
Non-invasive imaging with both cardiac CT and MR offers the unique opportunity to identify and quantify the presence, location and distribution of fat tissue within the heart in order to recognize different patterns of abnormality and differentiate abnormal from physiologic accumulations.
Spectrum of pathological conditions associated with abnormal fat accumulation is extremely variable including chronic or healed myocardial infarction (MI), arrhythmogenic RV cardiomyopathy or dysplasia (ARVC), cardiac lipoma and lipomatous hypertrophy of the interatrial septum, tuberous sclerosis complex, dilated cardiomyopathy, and cardiomyopathy with muscular dystrophy.
Present lecture will focus on current imaging criteria to differentiate between physiologic myocardial fat vs fat from various pathologic conditions at CT and MR imaging based on a literature review and personal experience.
Clinical and functional implications of fatty replacement will also be discussed and correlated with imaging appearance.

*Subepicardial fatty streak related to previous myocarditis*

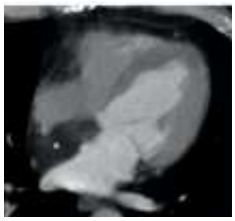

*Lipomatous hypertrophy of the heart with CT*

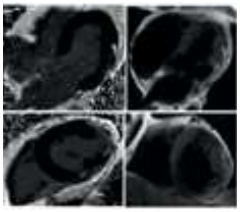

*Alcoholic-abuse related left ventricular wall fatty infiltration*

### Take Home Points

Combination of patient's clinical information and demographics, pattern of distribution of myocardial fat, myocardial thickness, and ventricular size helps in differentiating physiologic and pathologic myocardial fat at cardiac imaging.

## Cardiac tumours: Diagnosis and differentials

*F. Pontana; Lille/FR*

### Body

Recent improvement of spatial and temporal resolution in CT results in greater frequency of cardiac masses incidentally discovered in patients undergoing chest or cardiac CT angiograms for unrelated reasons. Cardiac masses are rare and can be categorised as either neoplastic or non-neoplastic. Approximately 75 % of neoplastic masses are benign with myxoma accounting for at least half of reported cases. Metastases are more common than primary malignant tumours. While echocardiography remains the first-line imaging modality, CT and MRI have become increasingly utilised modalities to assess cardiac masses. MRI is often the preferred imaging modality for cardiac masses because of its superior soft-tissue characterisation. However, CT offers an alternative in the diagnosis and surgical planning of cardiac masses owing to its high spatial and temporal resolution, fast acquisition time, and multi-planar image reconstructions. Diagnosis of cardiac masses is based on several analyses including size, quantity, location (cardiac chambers, valves, myocardium, pericardium), morphology (attachment, margin appearance, infiltration), tissue characteristics (calcification, fat, contrast enhancement), and clinical context (patient age, presence of a catheter, known malignancy or infection).

### Take Home Points

- CT can provide useful anatomical information in addition to echocardiography and MRI in the evaluation of cardiac masses.
- Primary cardiac tumours are mainly benign.
- Myxoma is the most frequent benign tumour.
- Metastases are more common than primary malignant tumours.
- Non-neoplastic cardiac masses such as thrombus or prominent normal anatomic structures can often mimic cardiac tumours.

## Pleuroparenchymal fibroelastosis

*S. Desai; London/UK*

### Body

Pleuroparenchymal fibroelastosis (PPFE) is relatively new entity, now recognised in the updated classification of the idiopathic interstitial pneumonias. PPFE is rare with the majority of publications, to date, restricted to case reports or small case series. The aetiology is not entirely clear but it seems likely that, in addition to cases of truly idiopathic disease, PPFE represents a response to some form of lung 'insult'. In published series, the putative associations of PPFE have included bone marrow & lung transplantation, recurrent chest infections and treatment with certain drugs. There is no gender predilection and most reports suggest that the majority are non-smokers. PPFE may be asymptomatic but, with progression, patients may report chest pain; clinical presentation with recurrent (apical) pneumothoraces is also recognised . On histopathological examination, there is fibrosis and elastosis of the visceral pleura and the adjacent (subpleural) lung, typically at the lung apices. Honeycombing is conspicuous by its absence and pathologists generally report a sharp demarcation between normal and abnormal lung. On imaging, the classical finding is that of bilateral pleural thickening and subpleural reticulation in the upper/mid zones, with or without pneumothoraces. Progressive dilatation of segmental / subsegmental airways may be seen if serial computed tomography (CT) examinations are available. Additionally, on CT, some patients will have a 'flattened' chest (i.e. a reduction in antero-posterior diameter). The lung remote from areas of PPFE may be abnormal with patterns of lung fibrosis including non-specific interstitial pneumonia and usual interstitial pneumonia.

### Take Home Points

Pleuroparenchymal fibroelastosis (PPFE) is a rare disorder characterised by upper zone pleural and subpleural thickening/fibrosis. PPFE may be idiopathic but associations with recuurent infection, bone marrow/lung transplantation and certain drug therapies has been reported. There are broadly recognisable imaging features which may allow the radiologist to suggest the diagnosis of PPFE.

## Molecular Imaging in Diffuse Lung Disease

*Ch. Haslett; Edinburgh/UK*

### Body

The diagnosis and management of diffuse pulmonary shadowing remains difficult in the clinic and in the ICU. In the clinic HRCT (which provides structural information only) has been helpful in sub-dividing interstitial lung diseases, but is less useful in assessing disease progress and is not practicable in the ICU. Positron-emission Tomography (PET) can provide very specific molecular signals in the lung, but resolution is poor and PET necessitates heavy and expensive machinery (scanners and a cyclotron) and it involves ionising radiation. The advent of in-vivo confocal microscopy via the flexible bronchoscope generates images down to the alveolar level, but on its own gives no specific cellular or molecular signals. Our novel approach has been to partner this technology with locally-delivered microdoses (<100ug) of molecular "SmartProbes" that are exquisitely sensitive and highly specific for their disease molecular targets.
New work will be presented on three bespoke SmartProbes, all of which are highly specific for their targets and release powerful fluorescent signals within seconds of target engagement: NAP a specific marker of activated human neutrophils. BAC-1 a specific marker of bacteria SmartProbe X specifically recognising enzymatic activity of a key element in fibrogenesis.

Recent unpublished experiments in human-size relevant models and in ex-vivo human lung will be presented to demonstrate the potential real-time bedside utility of this novel approach in rapidly determining the aetiology of diffuse lung shadowing in ICU patients and in monitoring the fibrogenic activity and response to new therapies in human ILD.

### Take Home Points

- Compact/bedside technology, readily applicable to lung
- No ionising radiation
- Specific molecular signals at alveolar resolution and detected within seconds
- Diagnosis, monitoring of treatment response and rapid facilitation of new drug design and validation

## IPF – Novel treatment options

*T. King; San Francisco/US*

### Body

Idiopathic pulmonary fibrosis (IPF) is characterized by progressive fibrosis and remodelling of the lung. IPF prognosis is poor with a median survival of 2 to 3 years from diagnosis. Unfortunately, many potential therapeutic options have been shown to be ineffective, with more than twenty negative clinical trials to date. However, several recent clinical trials have changed the management of IPF. The PANTHER trial showed that standard treatment with a combination of prednisone, azathioprine, and NAC was associated with an increased risk of death and hospitalization in patients with IPF. Consequently, this regimen is no longer used in such patients. Further, the use of acetylcysteine alone does not offer significant benefit with respect to the preservation of FVC in patients with IPF. Two new therapeutic agents - nintedanib and pirfenidone - have both demonstrated positive outcomes in major clinical trials (the INPULSIS-1 and INPULSIS-2 trials and the ASCEND trials respectively).

### Take Home Points

With increasing accessibility to these medications, clinicians will have to determine the suitability of their use in patients with different stages and/or phenotypes of IPF.

## ILD: Imaging in pharmacological trials

*D. Hansell; London/UK*

### Body

The role of high resolution CT (HRCT) for patients entering drug trials has expanded dramatically as the pharmaceutical industry has increasingly focused its efforts on developing drugs for idiopathic pulmonary fibrosis (IPF), and this has been spurred on by the recent successful introduction of two new drugs.

- HRCT has a key role in the appropriate selection of patients, despite the controversy surrounding the current diagnostic criteria for IPF. HRCT may also have a use in further refining patient cohorts for drug trials. To facilitate this "cohort enrichment" HRCT can be used to identify subgroups of patients who are stable (and thus unlikely to show a response to a novel treatment) or who are end-stage (and unlikely to respond).
- There is increasing interest in the potential for HRCT to be used as an endpoint, in conjunction with other markers, in drug trials. In several diseases mortality is not a suitable trial endpoint (largely because death may be relatively infrequent in the time span of a trial). Of the many markers that have been explored lung function (FVC) decline is currently the most widely used. However, now that there are disease-modifying treatments, capable of arresting or slowing disease progression, the need for markers more sensitive than FVC decline has become evident. As a result, combinations of endpoints (including HRCT) are now being investigated. A further role for HRCT is in early phase trials, as part of safety monitoring to identify adverse reactions to new agents.

### Take Home Points

HRCT is a key part of the diagnostic inclusion criteria for patients entering drug trials and may have a role in "cohort enrichment" of study populations in drug trials
Current exploration of HRCT in drug trials include its use as a co-endpoint and in safety monitoring
*Further reading:*
Fleischner society position paper on CT staging and monitoring of fibrotic interstitial lung diseases in clinical practice and therapeutic trials. Lancet Respiratory Medicine 2015 (in press).

## The Chest X-ray: Is it obsolete?

*L. Goodman; Milwaukee/US*

### Body

The chest x-ray has served well since the earliest days of x-ray imaging. It still has a valuable role in daily practice, but its role is changing as various competing modalities become available. It is still the most frequently performed medical imaging procedure.
Several prior applications are certainly obsolete such as imaging on hospital admission, preoperative imaging, *routine* daily portable radiographs, and following progress of lung cancer.
Projection imaging, however, is moving forward on multiple fronts including dual energy subtraction, temporal subtraction, alternate reconstruction algorithms, and tomosynthesis.
The biggest challenge will probably be to determine the role of ultra-low dose CT whose dose will make radiation exposure a less important issue in older adults.

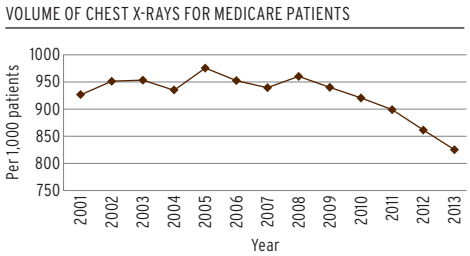


## The chest radiograph: Lung parenchyma

*G. Ferretti; Grenoble/FR*

### Body

CXR remains the keystone for the diagnosis of pulmonary diseases, as it is performed in the vast majority of patients complaining of chest symptoms, because is it largely available, simple to realize, low cost and delivers low radiation dose. However, indications of CXR for imaging the lung parenchyma are challenged by ultra-low dose HRCT.
In this presentation, I will focus on the remaining indications of CXR to investigate the lung parenchyma: lung infections in non-immunocompromised patients, patients with COPD, patients with sarcoidosis, patients admitted in the ER, patients in the ICU. Criteria defining a normal CXR, difficulties in the interpretation, and limitations will be discussed along with correlations with HRCT results.

### Take Home Points

- CXR has many limitations for imaging the lung parenchyma
- Appropriate indications of CXR should be known

## The azygos system

*J. Caceres; Barcelona/ES*

### Body

The azygos/hemiazygos system is a posterior venous pathway connected to the superior and inferior vena cava. The azygos vein ascends on the right side of the spine and arches anteriorly to join the SVC (azygos arch). The hemiazygos vein ascends on the left side and joins the azygos vein at the level of the 7th or 8th thoracic vertebra.
For practical purposes, the azygos arch is the only part of the azygos vein visible in the PA chest radiograph. It is seen end-on as a round or oval mediastinal shadow at the take-off of the RUL bronchus It is visible in about 10% of upright PA radiographs, and is always visible in supine films.
In the PA upright film, an azygos arch larger than 1 cm is considered abnormal and should be investigated. It is important to emphasize that the size of the azygos arch cannot be evaluated in supine films.
An azygos arch larger than 1 cm usually indicates increased blood flow in the azygos system. It may be non-obstructive or secondary to obstruction of the superior or inferior vena cava, in which case the azygos system acts as collateral drainage.
Azygos continuation of the IVC is a congenital anomaly in which the intrahepatic segment of the IVC is absent. Blood is shunted to the SVC through the azygos system. It occurs in about 1.5% of the population. It is an incidental finding in asymptomatic patients, usually discovered because of the enlarged azygos arch in the PA chest film.
The azygos lobe is a normal variant that is found in 1% of anatomic specimens and on about 0.4% of chest radiographs. It occurs when the right posterior cardinal vein, one of the precursors of the azygos vein, fails to migrate over the apex of the lung and penetrates it instead, carrying along pleural layers that entrap a portion of the right upper lobe.
The variants that can lead into error are: intrapulmonary pathways of the mediastinal veins, opaque azygos lobe andazygos continuation with an azygos lobe.

### Take Home Points

1. An azygos arch larger than 1 cm in upright PA films is considered abnormal and should be investigated.
2. The size of the azygos arch cannot be evaluated in supine films.
3. Non-obstructive causes of azygos enlargement are congestive heart failure and occasionally, portal hypertension.
4. Obstructive causes of azygos enlargement are thrombosis of the superior or inferior vena cava and, occasionally, partial congenital absence of the IVC.

## Common pitfalls in chest x ray diagnosis

*J. Vilar Samper; Valencia/ES*

### Body

The chest radiograph is the most common imaging study performed worldwide. The appearance of new imaging techniques has diminished the interest in reading Chest Radiographs. Thus the abilities developed during years are often forgotten giving rise to errors of interpretation that may lead to fatal consequences for the patients.
Errors in chest radiography may occur during the entire process, from the initial order from the referring physician, to the technician, the patient and the radiologist interpreting the examination.
The most common causes of erroneous interpretation of chest radiographs by the radiologists are:

1. Missing the lesion: This can be due to a) technical limitations such as overlap of structures, noise and spatial resolution, b) Lesion characteristics (size, density, location and morphology), c) reader´s limitations (perception, cognitive and fatigue).
2. Erroneous interpretation of the images: Simulations, normal variants.

How to minimize errors: Systematic reading and looking at specific areas in both projections. Adequate reading time and comparing with previous films. Obtaining always a lateral projection. The radiologist should have all the pertinent information from the technician and from the referring physician.

### Take Home Points

1. Errors in interpretation of chest radiographs are common
2. A systematic reading protocol is recommended with special atention to blind areas in both PA and Lateral projections.

## Missed lung cancer

*N. Howarth; Chêne-Bougeries/CH*

### Body

The presentation will cover the common and uncommon reasons for errors of interpretation of plain film and CT imaging of lung cancer. Missed lung cancers are one of the most frequent causes of malpractice issues. The skills required for accurate interpretation of plain film and CT imaging of the chest will be explored by a detailed interactive review of a wide variety of missed cancers. The objective is to help you to improve your performance in plain film and CT imaging of the chest.

### Take Home Points

1. To learn about the common and uncommon reasons for errors of interpretation of plain film and CT imaging of lung cancer.
2. To understand how a side-by-side comparison of the chest x-ray and MDCT of missed lesions can help reduce the busy radiologist's error rate.
3. To improve the skills required for accurate interpretation of plain film and CT imaging of the chest.

# EDUCATIONAL POSTERS

**P-0003** **Congenital bronchopulmonary diseases in adults: Pictorial essay**
N. Ceylan, S. Bayraktaroglu, R. Savas; Izmir/TR

**P-0004** **A pictorial review of unusual thoracic masses**
S. Singh, S. Karthik, A.L. Johnstone, M. Darby; Leeds/UK

**P-0005** **Imaging of esophageal cancer**
V.B. Antunes, R. Maciel, G. Meirelles, C. Figueiredo, A. Macedo-Neto, G. Szarf, I. Missrie, A. Silva, J. Capobianco; Sao Paulo/BR

**P-0007** **Neonatal chest X-ray for residents**
D. Uceda, S. Isarria, M.L. Domingo, A. Moreno, E. De la Via, A.T. Vizarreta, J. Vilar; Valencia/ES

**P-0009** **Lemierre's syndrome – The forgotten rare disease in young, healthy adults**
C. Lee, C.S.A. Lam, H.Y.L. Sinn, H.Y.S. Lam, W.W.M. Lam; Hong Kong/HK

**P-0014** **Anterior mediastinal masses: Spectrum of radiologic findings**
B. Alami, T. Ameuraoui, Z. Traoré, M.Y. Alaoui Lamrani, M. Boubbou, M. Maaroufi, S. Tizniti; Fes/MA

**P-0020** **Unusual tracheal tumors: A pictorial review**
S.L. Betancourt[1], D.M. Palacio[2], B. Carter[1]; [1]Houston/US, [2]Tucson/US

**P-0022** **If unnecessary CT scans are performing in our radiology unit; Retrospective study with comparing performed chest CT scans with previous chest graphics**
B. Tiryaki Bastug; Bilecik/TR

**P-0026** **Radiologic features of pulmonary sarcoidosis: A pictorial review**
N. Arcalis[1], P. Trallero[1], A. Elías Mas[2], J.A. Goday Arno[2], A. Collado[2], J.L. Fernandez[2], J. Bartrina Rosell[3]; [1]Granollers/ES, [2]Barcelona/ES, [3]Mataró/ES

**P-0027** **A case of pancreatic ductal adenocarcinoma with metastasis to the atypical supraclavicular region**
E. Üre, D.E. Tekcan Sanli, S. Bakan; Istanbul/TR

**P-0031** **Pulmonary veins CT: Imaging techniques, report and common ablation complications**
E. Chavarri Ibañez, A. Caldera, P. Rodríguez Fernández, A. Tilve Gómez, M.Á. Álvarez Moure, J. Vieito; Vigo/ES

**P-0034** **Pulmonary lymphangioleomyomatosis associated with tuberous sclerosis and double aortic arch**
M. Vukelic Markovic, J. Tekavec-Trkanjec, R. Huzjan-Korunic, M. Simic, B. Brkljacic; Zagreb/HR

**P-0037** **A rare but important complication of hydatid disease: Bronchobiliary fistula**
E. Üre, D.E. Tekcan Sanli, S. Bakan; Istanbul/TR

**P-0038** **When to suspect Wegener Granulomatosis: A radiologic review**
A. Tilve Gómez, R. Díez Bandera, P. Rodríguez Fernández, M. Garcia Vazquez-Noguerol, E. Chavarri Ibañez, R. Mendez, A. Illade Fornos, J. Vieito; Vigo/ES

**P-0040** **Rare radiologic findings of pulmonary sarcoidosis**
A.A. Demir, L. Soydan, A. Tunaci; Istanbul/TR

**P-0042** **A pictorial review of unusual lobar collpase**
K. Mullin, A. Gummow; Nottingham/UK

**P-0043** **Cavitary lung lesion: Two different diagnosis with similar appearence**
M. Yesildag, H. Kalkan, K. Ödev; Konya/TR

**P-0049** **Thoracic involvement in Kaposi sarcoma: An unexpected opponent in common scenarios**
A. Agustí, F. Zuccarino, M. Cufi, A. Gayete, F. Fernandez; Barcelona/ES

**P-0051** **Uncommon causes of atypical pneumonia: Increasing prevalence or increasing detection?**
K. Stefanidis, C. Sayer, D.A. Scobie, D.P. Riley, S. Grubnic, I. Vlahos; London/UK

**P-0052** **Extrapulmonary CT findings in diffuse cystic lung disease**
F. Zuccarino, F. Fernandez, M. Cufi, E. Balcells, E. Curto, L. Pijuan, A. Gayete; Barcelona/ES

**P-0055** **The pleura 2.0: Functional imaging and oncology applications**
J. Broncano[1], A. Luna[2], M.J. García-Velloso[3], R. García Figueiras[4], A. Alvarez-Kindelan[1], T. Martin[2], J. Sanchez[5]; [1]Córdoba/ES, [2]Jaen/ES, [3]Pamplona/ES, [4]Santiago de Compostela/ES, [5]Madrid/ES

**P-0056** **Spectrum of the congenital anomalies of the thoracic aorta**
J. Cambronero Gómez[1], G. Sánchez Núñez[1], P. Ortuño Muro[2], V. Cuba Camasca[1], G. Carbó Vilavedra[1], A. Gimeno Cajal[1]; [1]Girona/ES, [2]Sant Cugat del Valles/ES

**P-0057** **CT and MR manifestations of fibrosing mediastinitis**
M. Cufí Quintana, A. Fernandez, F. Zuccarino, A. Gayete; Barcelona/ES

**P-0058** **Uncommon causes of focal thoracic disease in young patients: A pictorial review**
T.R. Semple, P. Svrckova, A. Ahmed, M. Falzon, D. Brennand, P. Shaw, M. Taylor; London/UK

**P-0059** **For what must to know cardiac image, though you don´t devote yourself to it ...**
N. Gómez-Ferrera, J. Broncano, A. Luna, L.E. Rodríguez Delgado; Santa Cruz de Tenerife/ES

**P-0061** **HRCT of interstitial lung disease (ILD): The basic ingredients of the alphabet soup**
J. Broncano[1], F. Gutierrez[2], R. Reyna[3], S.E. Rossi[4], A. Luna[5]; [1]Córdoba/ES, [2]Saint Louis/US, [3]Panama/PA, [4]Buenos Aires/AR, [5]Jaen/ES

**P-0062** **Pulmonary aspergillosis: Spectrum of radiologic findings**
B. Alami, T. Lamia, Z. Traoré, M.Y. Alaoui Lamrani, M. Boubbou, M. Maaroufi, S. Tizniti; Fes/MA

**P-0063** **CT and PET/CT findings of BALTOMA**
R. Savas, N. Ceylan, S. Bayraktaroglu; Izmir/TR

**P-0067** **Lateral thinking: Do we need to perform lateral view of the chest as a routine?**
H. Khosa[1], T. Simelane[2], N. Ramesh[1]; [1]Portlaoise/IE, [2]Dublin/IE

**P-0068** **It's that lung lymphoma? Lets keep it simple! The practical pictorial atlas**
D. Penha, J. Ip, I. Duarte; Lisbon/PT

**P-0070** **Cystic lung diseases: Systematic approach and diagnostic challenges**
T. Rodrigues[1], A. Gomes[1], P. Campos[2], I. Távora[1]; [1]Lisbon/PT, [2]Cascais/PT

**P-0071** **Imaging features of Idiopathic Pulmonary Fibrosis: A pictorial review**
P. Leitão[1], A. Carvalho[1], R. Correia[1], B.M. Araujo[1], J. Goncalves[2]; [1]Porto/PT, [2]Oporto/PT

**P-0074** **Micronodular lung pattern – Differential diagnosis**
P. Ninitas[1], F. Marinho[2], P. Campos[3], I. Távora[1]; [1]Lisbon/PT, [2]Funchal/PT, [3]Cascais/PT

**P-0075** **Be easy with chest CT assessment of polymyositis and dermatopolymyositis**
M.L. Chabi, A.-L. Brun, O. Benveniste, P. Cluzel, P.A. Grenier; Paris/FR

**P-0076** **Pulmonary alveolar microlithiasis**
I. Willekens, B. Ilsen, J. de Mey; Brussels/BE

**P-0077** **The great mimic: Pictorial review of differential diagnoses of pulmonary sarcoidosis**
J.P.A. Lopes, M. Simões, O. Fernandes, L. Figueiredo; Lisbon/PT

**P-0078** **State of the art clinical and radiologic imaging and management of ARDS**
K. Stefanidis, C. Sayer, S. Grubnic, I. Vlahos; London/UK

**P-0079** **Non-neoplastic pulmonary and pleural mass-like lesions. Imaging findings and clinical considerations**
D.M. Palacio[1], S.L. Betancourt[2]; [1]Tucson/US, [2]Houston/US

**P-0085** **Pulmonary parenchymal complications of pulmonary venous occlusion following radiofrequency ablation for atrial fibrillation: Report of two cases**
H. Robbie, O. Romanos, K. Stefanidis, S.D. Tran, N. Gall, J. Silberbauer, S.R. Desai; London/UK

**P-0086** **Did you mark the retrosternal air space on your check-list?**
A. Villanueva Marcos[1], M. Siddiqui[1], M. Escobar[2]; [1]Cambridgeshire/UK, [2]Barcelona/ES

**P-0087** **Role of imaging in pleural infection**
S. Hernandez Muñiz[1], P. Olmedilla[2], J. Carrero[2], J.C. Albillos Merino[3], S. Morón Hodge[1]; [1]San Sebastian de los Reyes/ES, [2]Alcorcón/ES, [3]Madrid/ES

**P-0089** **Thoracic manifestations of collagen vascular diseases: Common aspects and major differences**
T. Rodrigues[1], P. Campos[2], I. Távora[1]; [1]Lisbon/PT, [2]Cascais/PT

**P-0090** **Systemic lupus erythematosus and the lung: A pictorial review**
A. Carvalho, P. Leitão, M.S.C. Rodrigues, B.M. Araujo, N.P. Silva; Porto/PT

**P-0092** **Pulmonary tumor embolism: What the radiologist needs to know**
D. Preciado Borreguero, E. Castañer González, M. Andreu Magarolas, X. Gallardo, B. Consola, V.P. Beltrán Salazar, J.M. Mata Duaso, I. Costa; Sabadell/ES

**P-0093** **Pulmonary tuberculosis a new look at an old disease: Atypical manifestations and uncommon complications**
V.P. Beltrán Salazar, E. Castañer González, X. Gallardo, M. Andreu, J.M. Mata Duaso; Sabadell/ES

**P-0094** **Current surgical concepts in malignant pleural mesothelioma for radiologists**
P.M. de Groot, M.C.B. Godoy, B. Carter, D. Rice, R. Munden; Houston/US

**P-0095** **Radiological findings and complications of endobronchial treatment for lung volume reduction (LVR) in patients with severe emphysema: Our experience**
A. Utrera, A. Alcazar, G. Gallardo Madueño, A. Alonso Burgos; Madrid/ES

**P-0096** **Dry pleural disease: Imaging findings and differential diagnosis**
J. Arenas-Jimenez, E. García-Garrigós, J.M. Bernabé-García, C. García-Espasa, M.D. Guirau-Rubio, J. De la Hoz-Rosa; Alicante/ES

**P-0099** **Going down the pipes: A pictorial review of endobronchial lesions**
S. Tripathi, R. Dickens, K. Jayawardhana, P. McParland, A. Wallis; Portsmouth/UK

**P-0100** **Non-Thrombotic Pulmonary Emboli**
S. Karia, D. Gopalan, A. Balan; Cambridge/UK

**P-0101** **What lies beneath the diaphragm?**
H. Khosa[1], T. Simelane[2], N. Ramesh[1]; [1]Portlaoise/IE, [2]Dublin/IE

**P-0102** **The mediastinum – Its importance in the workup of pulmonary hypertension**
S. Karia[1], A. Barker[2], N.F. Bassett[1], K. Tweed[1], N.J. Screaton[1]; [1]Cambridge/UK, [2]Norwich/UK

**P-0104** **Lung volume reduction surgery and endobronchial valves in emphysema – What every chest radiologist should know?**
R. Chittal[1], D. Oswal[2], C.M. Exley[3], A.O.C. Johnson[2]; [1]Leeds/UK, [2]Wakefield/UK, [3]Dewsbury/UK

**P-0105** **Medical tubes and devices seen on the chest radiograph**
H. Khosa, S. Arockiam, K. Sunkari, N. Ramesh; Portlaoise/IE

**P-0106** **A schematic approach to mediastinal masses**
F. D'alessandro[1], M. Mereu[2], M. Verdecchia[3], A. Giammarini[2], M.C. Torrione[2], R.L. Patea[2], A. Cotroneo[2]; [1]Notaresco/IT, [2]Chieti/IT, [3]Avezzano/IT

**P-0107** **Alveolar and interstitial syndromes: Which to choose?**
M. Verdecchia[1], M. Mereu[2], F. D'alessandro[3], A. Giammarini[2], R.L. Patea[2], A.R. Cotroneo[2]; [1]Avezzano/IT, [2]Chieti/IT, [3]Notaresco/IT

**P-0108** **Spectrum of chest injuries in polytrauma - A pictorial review**
R. Chittal, A.L. Johnstone, M. Darby; Leeds/UK

**P-0109** **New kid on the block – A review of the radiological findings of Pleuroparenchymal Fibroelastosis (PPFE)**
K. Jayawardhana, R. Martins, R. Dickens, A. Ismail, S. Tripathi, P. McParland, A. Wallis; Portsmouth/UK

**P-0110** **Granulomatosis with polyangiitis: Thoracic findings at CT**
M. Nogueira[1], D. Castelo[1], A.C. Silva[1], C. Moreira[1], I. Rolla[2], J.A. Machado[1]; [1]Porto/PT, [2]Matosinhos/PT

**P-0111** **Posterior mediastinal masses - An important challenge of chest imaging**
H. Alboi-Sandru[1], M.M. Coman[2], M.T.A. Buzan[3], I.-A. Brumboiu[4]; [1]Cluj-Napoca/RO, [2]Campia Turzii/RO, [3]Blaj/RO, [4]Cluj/RO

**P-0112** **UIP, NSIP and OP patterns. Benefit of ancillary findings**
M. Gutiérrez Gimeno; Barcelona/ES

**P-0113** **Pulmonary infections in children – Multimodality evaluation**
A.S. Teixeira Gomes, M.S.R.O. Faustino, L. Lobo, I. Távora; Lisbon/PT

**P-0114** **The different faces of Nonspecific Interstitial Pneumonia**
M. Simões; Lisbon/PT

**P-0115** **Radiologic findings of drug-induced lung disease**
A.I.C. Santos, A.F. Roque, R. Mamede, L. Oliveira, T. Saldanha; Lisbon/PT

**P-0116** **Atlas of thoracic vascular variants – Why shouldn´t we miss it?**
R. dos Santos, C. Leal, H.M.R. Marques, M. Simões, N. Costa, O. Fernandes, L. Figueiredo; Lisbon/PT

**P-0117** **Back to basics: Coronary arteries anatomical variants and anomalies – A pictorial review using coronary CT angiography**
M.T.A. Buzan[1], A. Nair[2], M.M. Coman[1], E. Woo[3], R. Preston[2]; [1]Cluj-Napoca/RO, [2]London/UK, [3]Aylesbury/UK

**P-0119** **Multi modality assessment of the pulmonary arteries: Distinguishing pulmonary artery sarcoma from chronic thromboembolic pulmonary hypertension**
N.F. Bassett, J. Tanner, S. Karia, K. Tweed, N.J. Screaton; Cambridge/UK

# SCIENTIFIC POSTERS

**P-0001** **Hepatopulmonary Fistula – A life threatening complication of Hydatid Disease**
M. Gulamhussein, D. Patrini, J. Pararajasingham, B. Adams, D. Lawrence, N. Panagiotopoulos; London/UK

**P-0002** **Lung morphology assessment of cystic fibrosis using PETRA sequence at 1.5 Tesla**
G. Dournes[1], J. Macey[1], F. Menut[1], M. Fayon[1], M. Montaudon[2], O. Corneloup[2], J.-F. Chateil[1], F. Laurent[2]; [1]Bordeaux/FR, [2]Pessac/FR

**P-0006** **Pleural Plaques in 310 Asbestos-Exposed Workers: CT Characteristics**
Y. Kim[1], J.S. Kim[2]; [1]Seoul/KR, [2]Gyeonggi-do/KR

**P-0008** **Asbestos-related Pleural Plaques: Radiographic and CT Correlation**
Y. Kim[1], J.S. Kim[2], Y.K. Kim[3]; [1]Seoul/KR, [2]Gyeonggi-do/KR, [3]Incheon/KR

**P-0010** **MDCT and MRI in post infectious obliterate bronchiolitis after different types of viral infections**
A. Ivkovic, T. Milosavljevic, S. Ivkovic; Nis/RS

**P-0011** **Boyd OODA loop and Wilcoxon rank sum test in diagnostic after major disasters with lung injuries**
A. Ivkovic, T. Milosavljevic, D. Ivkovic, S. Ivkovic; Nis/RS

**P-0012** **Suicidal attempt; Lung MDCT with angiography and perfusion and MRI with DWI in diagnostic and following**
A. Ivkovic, T. Milosavljevic, S. Ivkovic; Nis/RS

**P-0013** **Usefulness of diffusion-weighted (DWI) magnetic resonance and MDCT for distinguishing sarcoma from other thoracic wall masses**
T. Milosavljevic, A. Ivkovic, S. Ivkovic; Nis/RS

**P-0015** **MDCT and MRI differences between cardiac edema, viral pneumonia and ARDS**
T. Milosavljevic, A. Ivkovic, S. Ivkovic; Nis/RS

**P-0016** **MDCT and MRI differences between child and adult cases of pulmonary sequestration**
T. Milosavljevic, A. Ivkovic, S. Ivkovic; Nis/RS

**P-0017** **Mesothelioma: Can histological subtypes be differentiated on computer tomography?**
R. Dickens, A. Ismail, R. Martins, K. Jayawardhana, S. Tripathi, A. Wallis, P. McParland; Portsmouth/UK

**P-0018** **Mass lesions and cysts of mediastinum**
H. Kalkan, K. Ödev, B. Apıllıoglu, S. Ceran; Konya/TR

**P-0019** **Magnetic resonance imaging in pulmonary embolism: Diagnostic accuracy of unenhanced steady-state-free-precession sequence and its effect on mortality rates**
B. Hochhegger[1], G. Alves[1], C.S. Nin[1], R. Amaral[1], K.L. Irion[2], E. Marchiori[3]; [1]Porto Alegre/BR, [2]Liverpool/UK, [3]Rio de Janeiro/BR

**P-0021** **Computed tomographic pulmonary changes in patients with chronic rhinosinusitis**
B. Hochhegger[1], G. Alves[1], C.S. Nin[1], V. de Souza[1], R. Amaral[1], K.L. Irion[2], E. Marchiori[3]; [1]Porto Alegre/BR, [2]Liverpool/UK, [3]Rio de Janeiro/BR

**P-0023** **Correlation of computed tomography with surgical findings in decortication and pleural drainage**
A. Yen, J. Padwal, K. Nakanote, S. Kao, P. Thistlethwaite, S. Brouha; San Diego/US

**P-0024** **Radiologic findings in COPD patients: Consistent vs. inconsistent clinico-radiologic features**
B.D. Nam[1], S. Ko[1], J.H. Hwang[1], Y.M. Lee[1], J.S. Park[1], S.S. Jou[1], Y. Kim[2]; [1]Seoul/KR, [2]Cheonan/KR

**P-0025** **Lung cancer in patients with chronic empyema**
Y. Lee, C.-K. Park; Guri/KR

**P-0028** **Detection and morphological analysis of breast tumors in chest CT; Correlation with ultrasonography and mammography**
H. Kang, E.M. Cho, Y.G. Shin; Busan/KR

**P-0029** **Performance of half-dose chest CT in lung malignancy using a new iterative reconstruction technique**
H. Kang, B.S. Kim, J.G. Park; Busan/KR

**P-0030** **Effectiveness of radiological monitoring of subcentimeter pulmonary nodules incidentally detected**
M. Garcia Vazquez-Noguerol, V. Leiro, P. Rodriguez, E. Chavarri Ibañez, M. Botana Rial, A. Tilve Gómez, J. Vieito, A. Fernández Villar; Vigo/ES

**P-0032** **Clinical Evaluation of Content-based Image-Retrieval System in CT diagnosis for lung cancer**
M. Endo, K. Asakura, T. Aramaki, E. Bekku, R. Sato; Shizuoka/JP

**P-0033** **Outcome of CT guided FNA of small lung lesions in cooperation with a cytologist present; Preliminary results**
S. Nyren, J. Pawlowski, E. Radecka, V. Svjatoha, P. Lindholm; Stockholm/SE

**P-0035** **Image quality yielded by different chest tomosynthesis protocols – A phantom study**
S. Nyren[1], M. Jadidi[1], P. Lindholm[1], M. Bath[2]; [1]Stockholm/SE, [2]Gothenburg/SE

**P-0036** **Pulmonary legionellosis: Characteristic findings on chest CT**
G.S. Shroff, C.C. Wu, E.M. Marom, A. Ihegword, X.-Y. Han, M.T. Truong; Houston/US

**P-0039** **Specific signs of thoracic aorta traumatic rupture on chest X-ray of high energy trauma patients**
E. Kocova, J. Koci, R. Hyspler, J. Raupach; Hradec Kralove/CZ

**P-0041** **Takayasu arteritis: Evaluation with contrast enhanced three-dimentional MR Angiography**
H. Kalkan, K. Ödev, E. Emlakcıoglu, R. Tunç, B. Ataç; Konya/TR

**P-0044** **CT and MR imaging evaluation of chest wall disorders**
K. Ödev, H. Kalkan, M. Yesildag, S. Ceran, N. Poyraz; Konya/TR

**P-0045** **Tracheoesophageal and bronchoesophageal fistula**
K. Ödev, H. Kalkan, C. Korkmaz, M. Koc, Z. Er, M. Artaç, S. Ceran; Konya/TR

**P-0046** **Diagnostic and follow-up CT findings in a cohort of patients with thoracic sarcoidosis**
T. Gamo Jiménez, M. Rodríguez Masi, J. Ferreiros, A. Bustos, B. Cabeza; Madrid/ES

**P-0047** **Study of relationship between ground-glass opacities and functional tests at patients with scleroderma**
J. Vanásek, E. Kocova, T. Soukup; Hradec Kralove/CZ

**P-0048** **Effectiveness of lung cancer rapid unit in our area**
P. Rodríguez Fernández, A. Tilve Gómez, M. Botana Rial, E. Chavarri Ibañez, V. Leiro, J. Vieito, A. Fernández Villar; Vigo/ES

**P-0050** **Lung magnetic resonance imaging for complications of lower airway tract infection in children**
J. Mueller, J.-P. Schenk, A. Alrajab, H.-U. Kauczor, O. Sommerburg, M. Mall, M.O. Wielpütz; Heidelberg/DE

**P-0053** **Lung adenocarcinoma: Correlation between CT and pathological findings**
E. Serrano Tamayo, M. Muñoz Del Blanco, A. Bustos, B. Cabeza, I. de la Pedraja, J. Ferreiros; Madrid/ES

**P-0054** **Pleural empyema associated with mycobacterium avium complex lung disease**
H.J. Yoon, M.J. Chung, M.J. Cha, K.S. Lee, J.S. Kim, H.Y. Park, W.-J. Koh; Seoul/KR

**P-0060** **Role of F-18 FDG PET-CT in the evaluation of small (**
S. Vaidyanathan, T. Vamadevan, R. Naveen, S. Karthik, A.F. Scarsbrook; Leeds/UK

**P-0064** **Retroperitoneal and intradiaphragmal location of bronchogenic cyst**
R. Huzjan Korunic, M. Vukelic Markovic, T. Stoos Veic, J. Curic, B. Brkljacic; Zagreb/HR

**P-0065** **Bronchoscopic volume reduction with lung sealant in severe emphysema: CT evaluation of pulmonary volume changes and correlation with clinical outcome**
L. Flors Blasco, J.L. Camacho, M.P. Calvillo, E. Cases, J. Patrie, K.D. Hagspiel, C. Leiva-Salinas; Charlottesville, VA/US

**P-0066** **Intraoperative ultrasound-guided resection of subsolid pulmonary nodules**
I. Vollmer, L. Pijuan, R. Aguiló, J. Belda, A. Rodríguez-Fuster, F. Zuccarino, M. Cufi, A. Gayete; Barcelona/ES

**P-0069** **CT angiography findings in infarction due to chronic pulmonary embolism (CPE)**
B. Consola, E. Castañer González, M. Andreu, X. Gallardo, V. Beltrán, D. Preciado Borreguero; Sabadell/ES

**P-0072** **Accuracy of Ultra low dose CT versus standard dose CT in CT densitometry of the lung in patients with COPD**
C.O Brien, H.K. Kok, E. O' Dwyer, S. Lane, O. Buckley; Dublin/IE

**P-0073** **Diffuse Idiopathic Pulmonary Neuroendocrine Cell Hyperplasia (DIPNECH) and multicentric carcinoid tumour spectrum: Terminology, classification and CT findings**
S. Otero, J. Jacob, A.G. Nicholson, A. Devaraj, S.P.G. Padley; London/UK

**P-0080** **MRI in fungal lung diseases: Correlation with chest CT**
A.P. Sartori[1], F. Gazzoni[1], A.S. Souza Jr.[2], E. Marchiori[3], L.C. Severo[1], B. Hochhegger[1]; [1]Porto Alegre/BR, [2]Sao Jose do Rio Preto/BR, [3]Rio de Janeiro/BR

**P-0081** **Pulmonary tuberculosis presented with right middle lobe syndrome: CT and clinical characteristics**
K.N. Jeon, K. Bae; Jinju/KR

**P-0082** **Image-guided thoracic biopsy in the younger population – A 5 year retrospective review of histology proven thoracic disease in 11-35 year olds**
T.R. Semple, P. Svrckova, M. Falzon, D. Brennand, M. Taylor, P. Shaw, A. Ahmed; London/UK

**P-0083** **Radiological variants of pulmonary sarcoidosis in dynamic monitoring**
I. Sokolina, I. Koroleva; Moscow/RU

**P-0084** **Efficacy of computed tomography with model-based iterative reconstruction in lung nodule detection at the radiation dose compared to plain radiography**
K.K. Lau[1], D.M. Jackson[2]; [1]Melbourne/AU, [2]Clayton/AU

**P-0088** **The effect of multiphasic injection protocol on routine contrast-enhanced chest CT using 128-MDCT: Comparison with uniphasic injection protocol**
K.N. Jeon, K. Bae; Jinju/KR

**P-0091** **Pleuropulmonary blastoma**
B. Özkul[1], A. Akça[2], B. Kalaycıoglu[1], F. Corapcıoglu[1], Y. Anik[1]; [1]Kocaeli/TR, [2]Istanbul/TR

**P-0097** **Image guided lung biopsies: Evolving experience in a large UK district general hospital**
A. Ismail, R. Dickens, R. Martins, K. Jayawardhana, P. McParland, R. Clark, E. Heiden, A. Wallis; Portsmouth/UK

**P-0098** **The use of digital tomosynthesis for „bedridden" patients with suspected inflammatory lung diseases**
V. Nechaev; Moscow/RU

**P-0103** **Assessing the safety and efficacy of radiation dose reduction in centers lacking iterative reconstruction**
R. Martins, K. Jayawardhana, A. Ismail, S. Tripathi, R. Dickens, A. Wallis, P. McParland; Portsmouth/UK

**P-0118** **Perfusion CT in the response evaluation in patients with advanced non-small cell lung cancer treated with conventional and anti-angiogenic chemotherapy: IMPACT study**
M. Benegas Urteaga, M. Sanchez, A. Sosa, I. Vollmer, N. Reguart; Barcelona/ES

**P-0120** **Pitfalls and artifacts in FDG oncologic PET/CT: A pictorial essay to the thoracic radiologist**
G. Meirelles, J. Capobianco, M. Oliveira; Sao Paulo/BR

**P-0121** **A case report: Recurrent vocal cord pyogenic granuloma**
D.E. Tekcan, I. Adaletli, E. Üre; Istanbul/TR

# POTENTIAL CONFLICT OF INTEREST DISCLOSURES

It is the policy of the European Society of Thoracic Imaging to ensure balance, independence, objectivity, and scientific rigour in the congress programme. Knowledge of possible relationships with sponsors of any kind is mandatory in order to reinforce the educational and scientific message and to relieve any suspicion of bias. Any potential conflict of interest involving the organising committee should be made known so that the audience may form their own judgements about the presentation with a full disclosure of the facts. It is for the audience to determine whether the presenter's external interest may reflect a possible bias in either the work carried out or the conclusions presented.

The congress president, Dr. Tomás Franquet, did not disclose any relationships.

ESTI

European Society of Thoracic Imaging

# ESTI 2016

24th ANNUAL SCIENTIFIC MEETING OF THE EUROPEAN SOCIETY OF THORACIC IMAGING

**MAY 26-28, 2016**

ISTANBUL, TURKEY

WWW.MYESTI.ORG


**ESTI Office**
Neutorgasse 9/2 | 1010 Vienna | Austria
Phone +43 1 532 21 65 | Fax +43 1 253 30 33-1328 | office@myESTI.org
www.myESTI.org